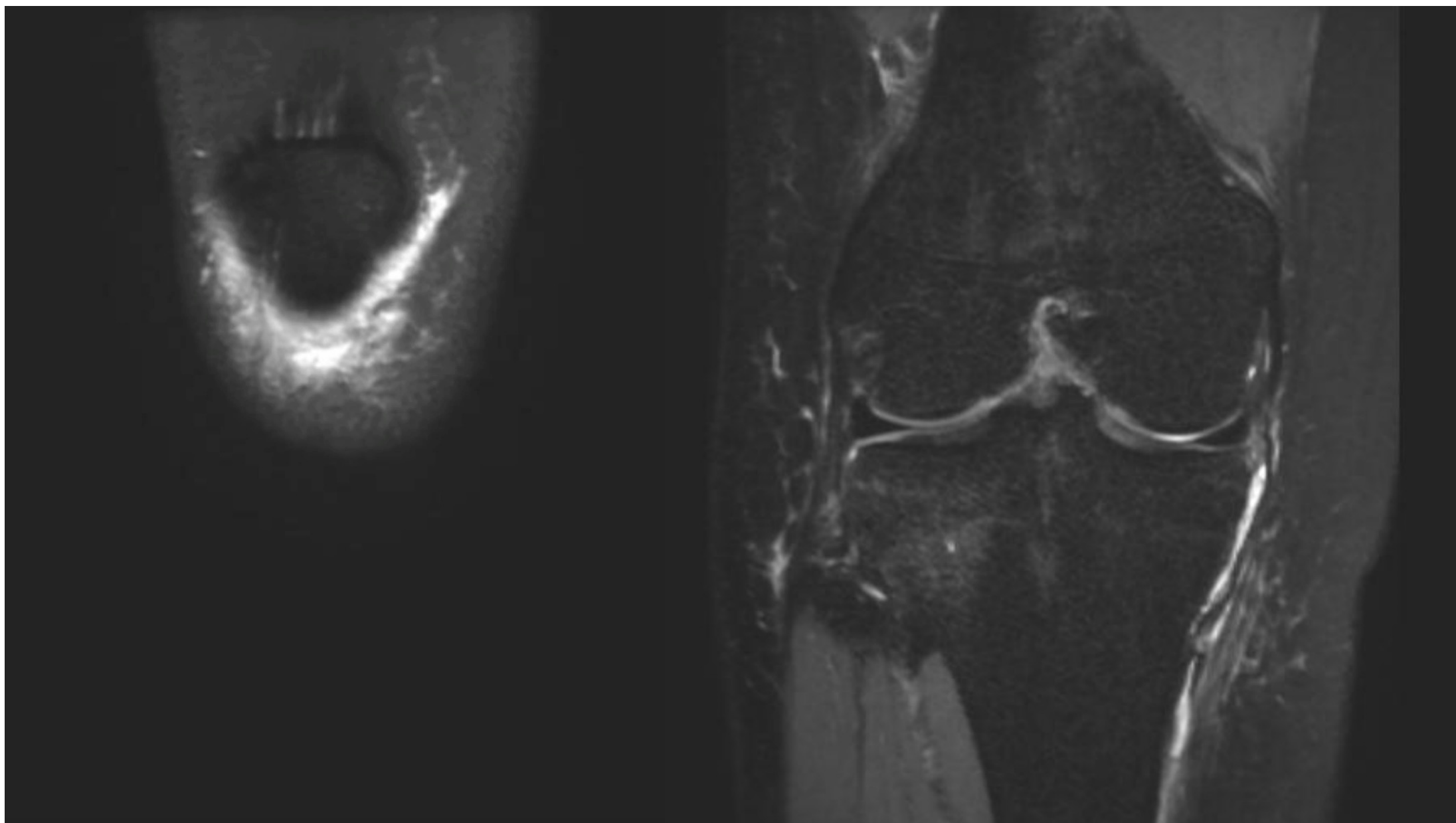
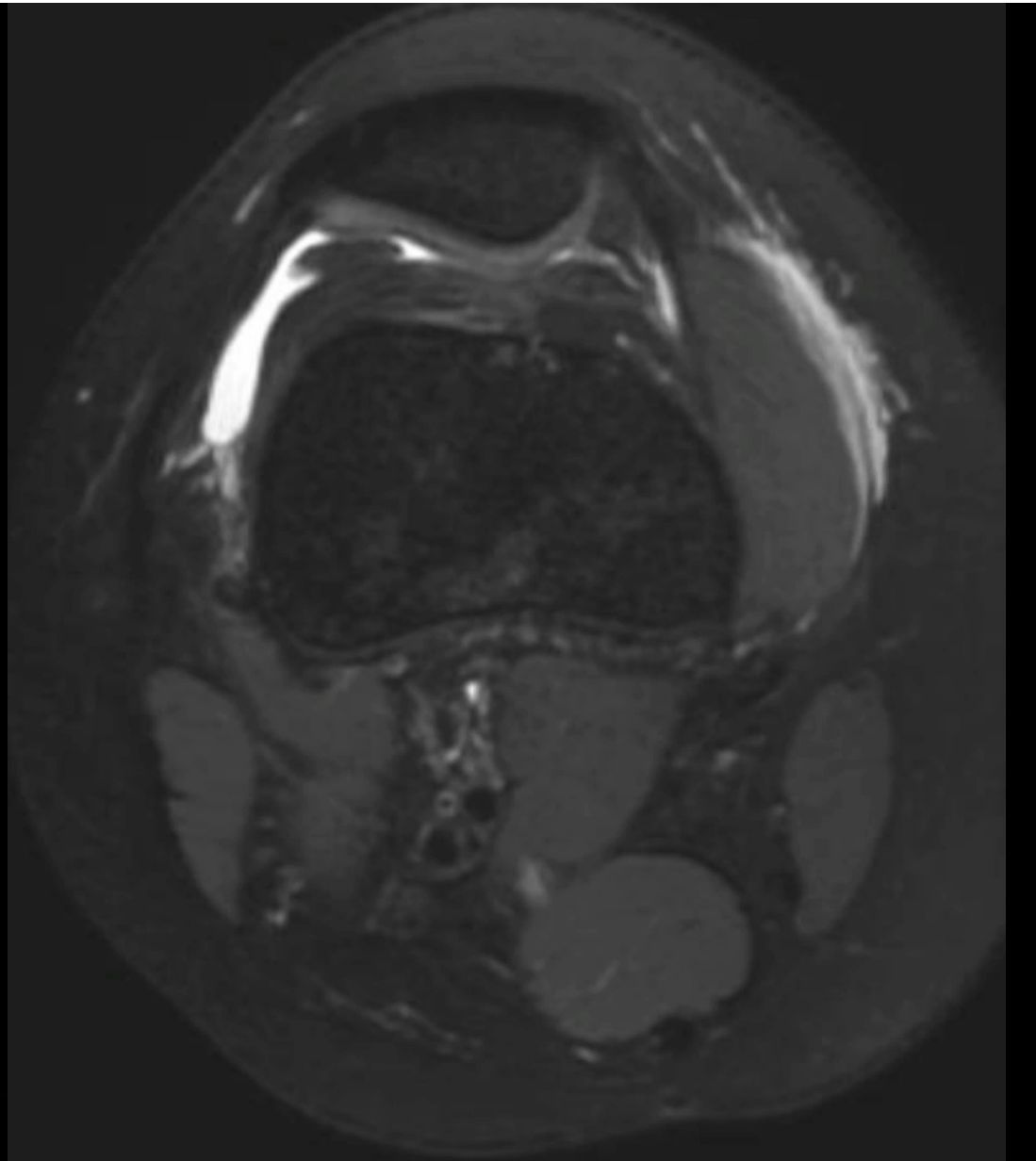
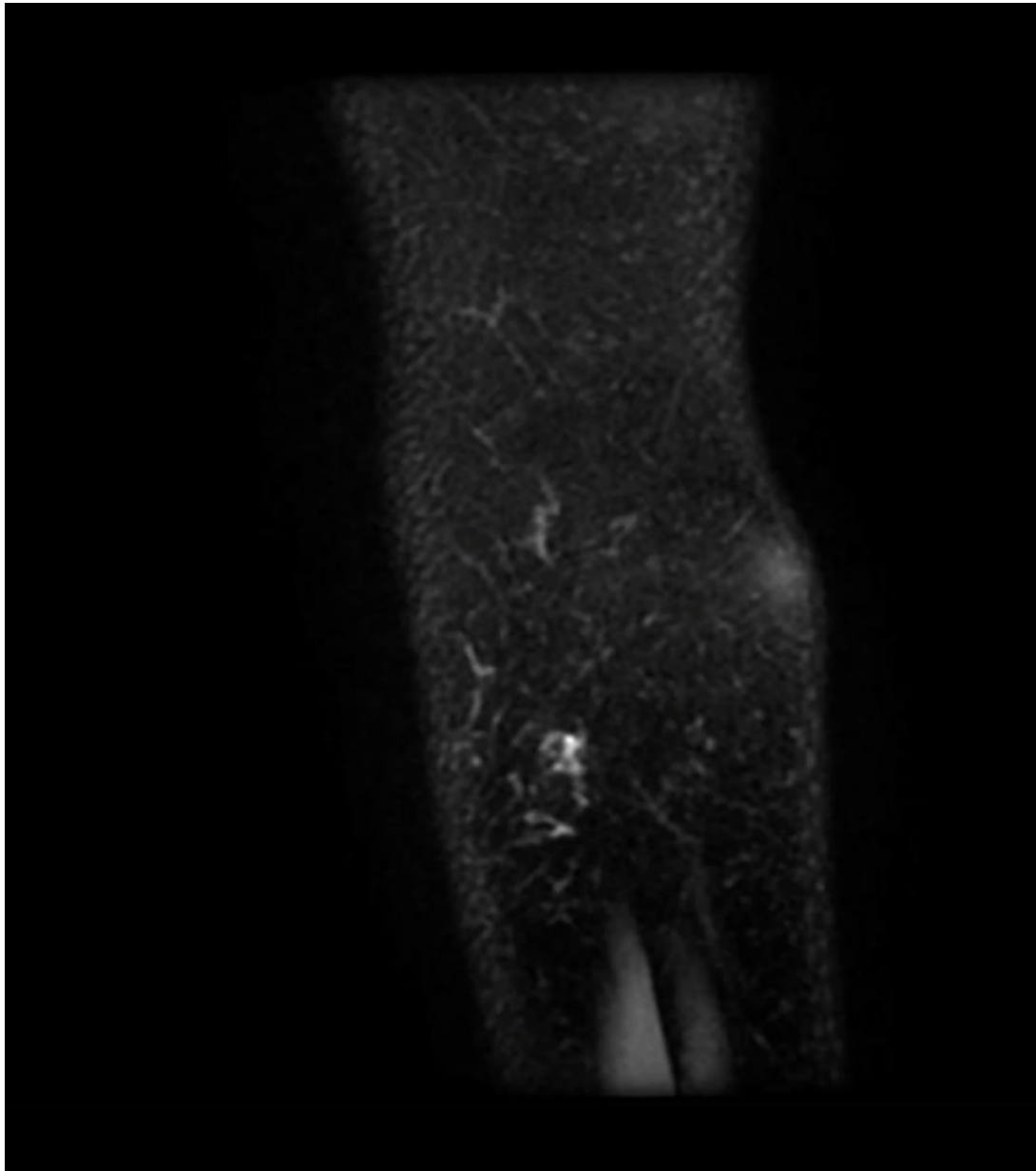


1st Case: 17 y.o. female Rugby Player

- Tackle injury 3 weeks ago
- Clinical exam in my office
 - Valgus deformity (1 hand)
 - ROM 0/0/130
 - Lachman soft end-point
 - Glide Pivot Shift
 - KT1000 13/7- Side To Side Diff 6mm
 - Moderated medial laxity in flexion and in extension (<15°)





Any comment on this MRI ?

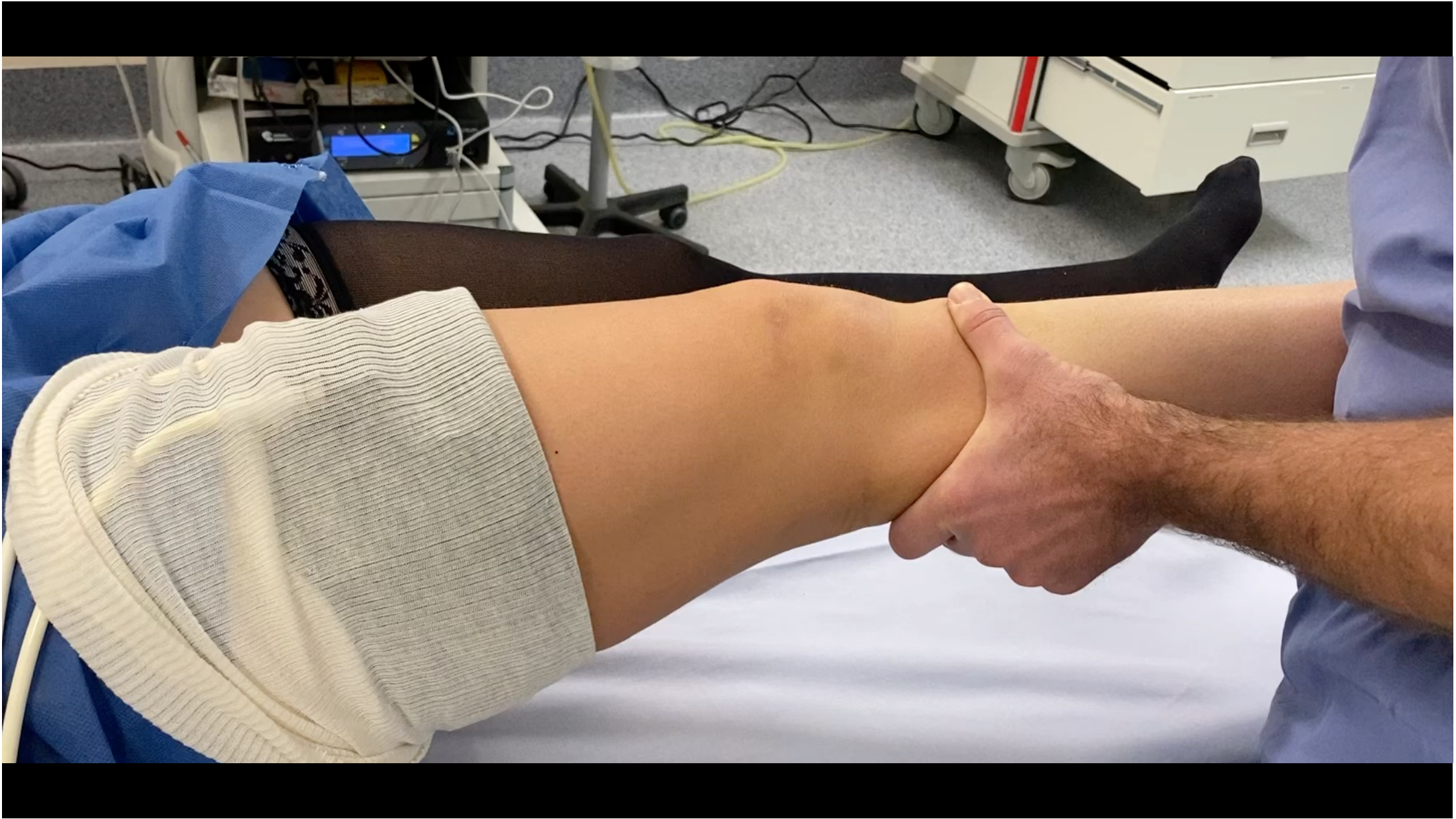
What is your treatment strategy ?

Type of graft?

When performing surgery?

Medial approach?

Post-operative care?



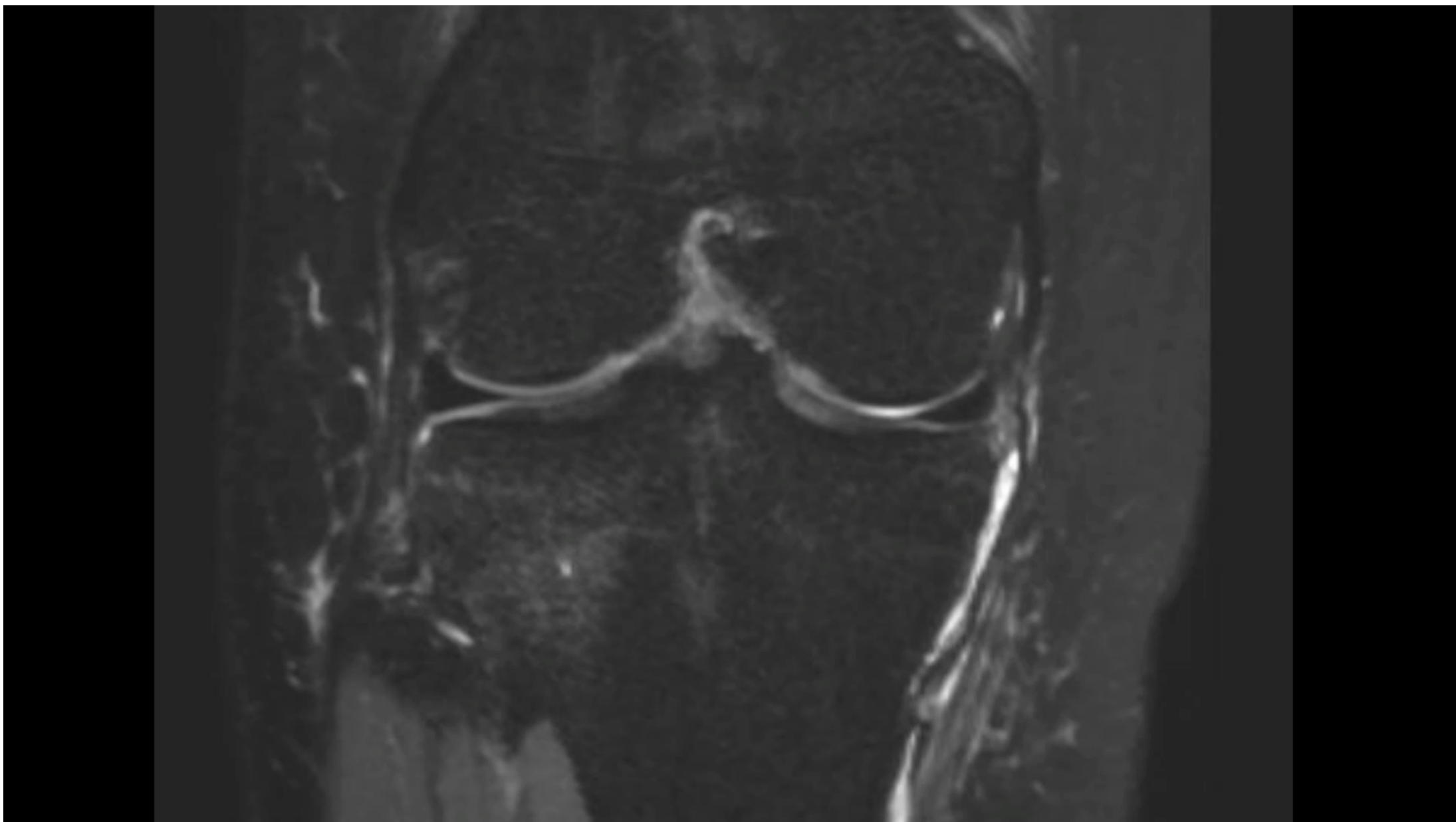
Do you change your treatment strategy?

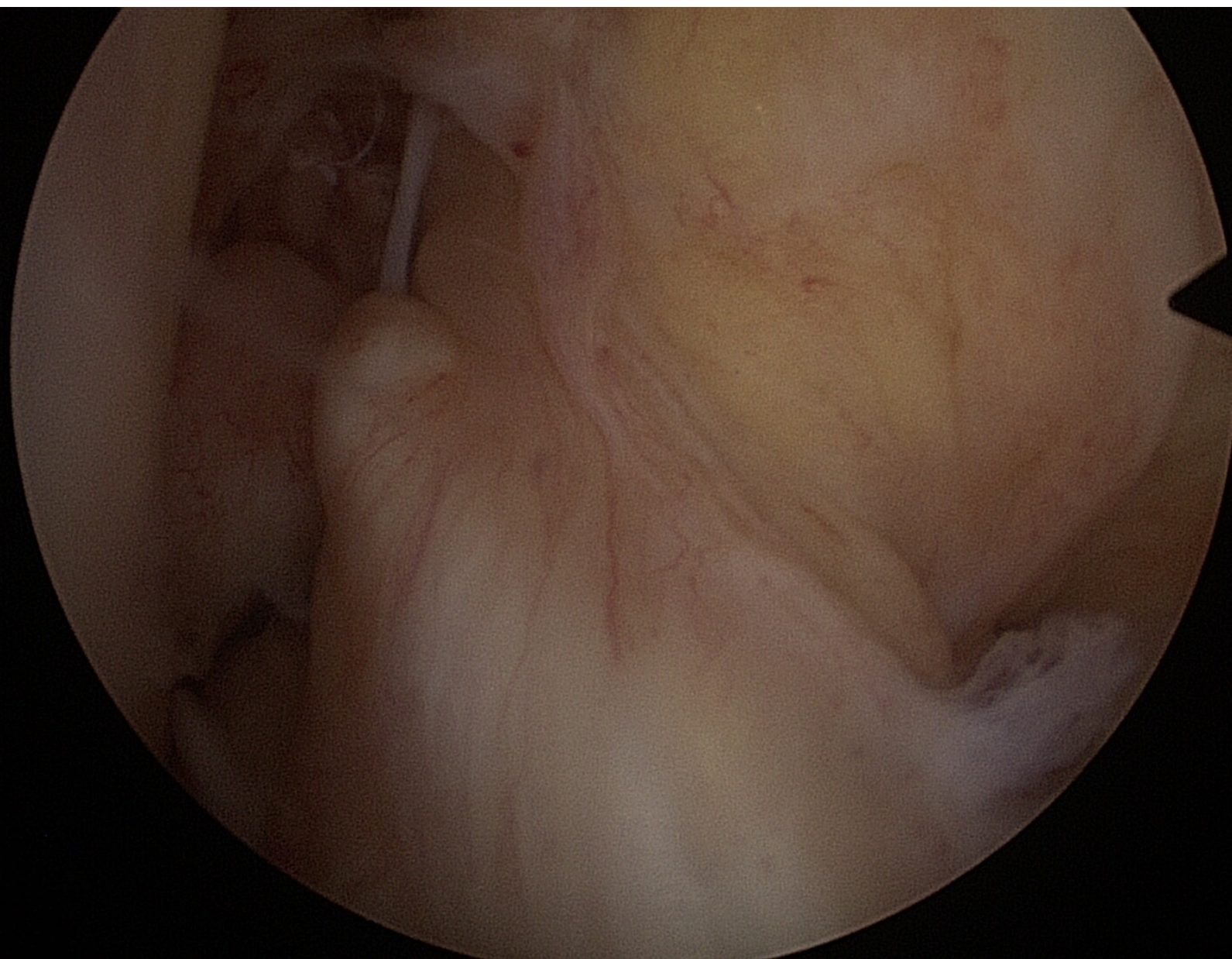
Type of graft?

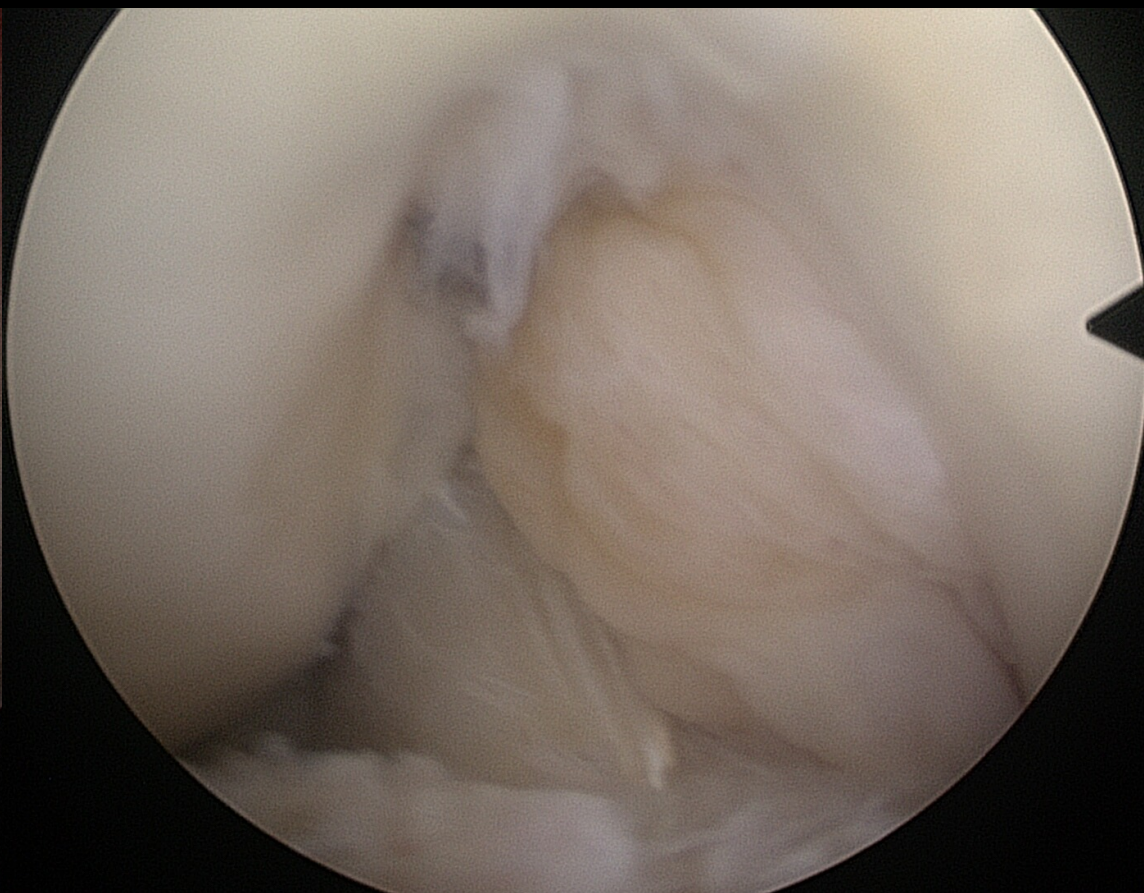
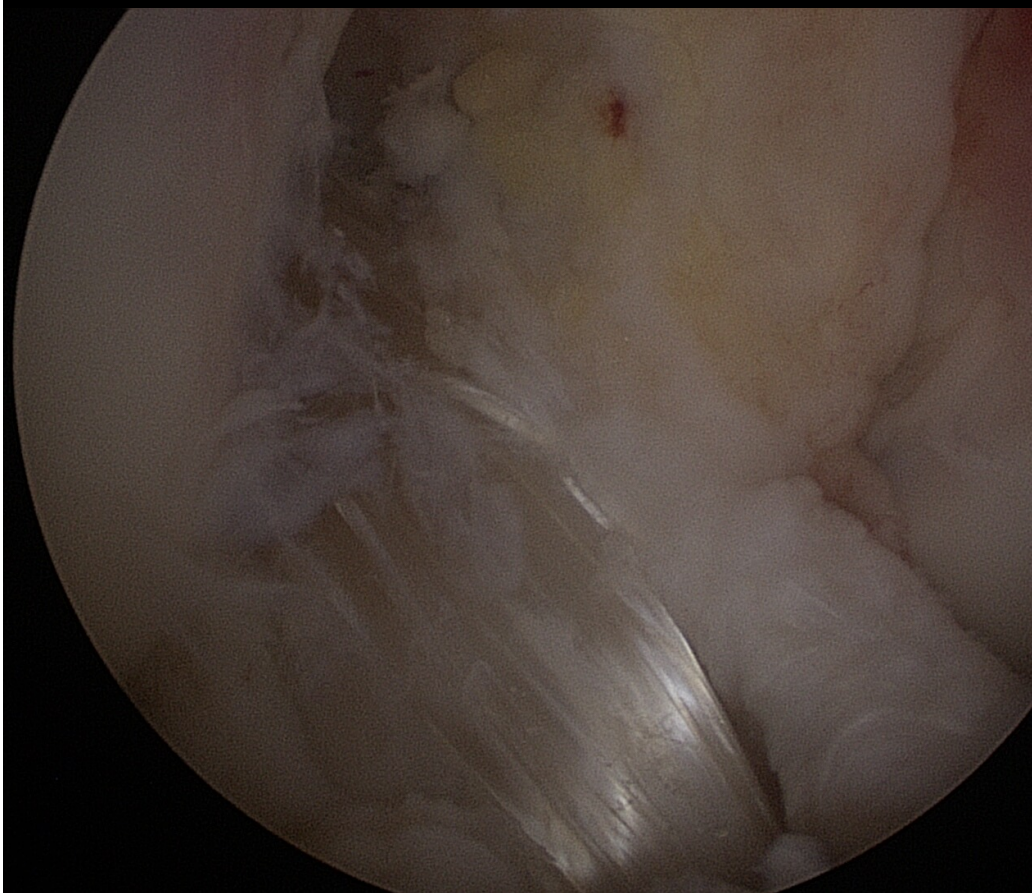
When performing surgery?

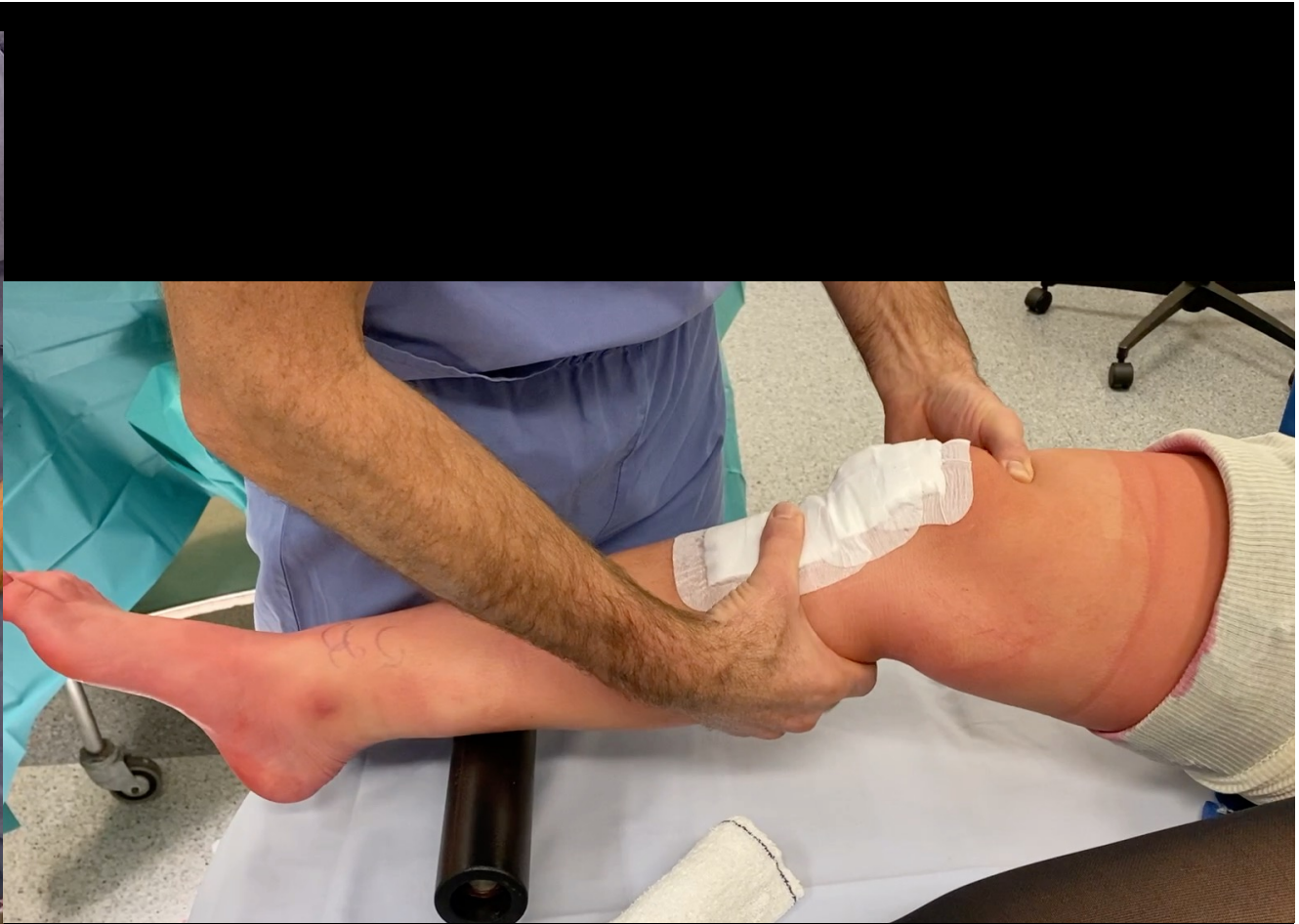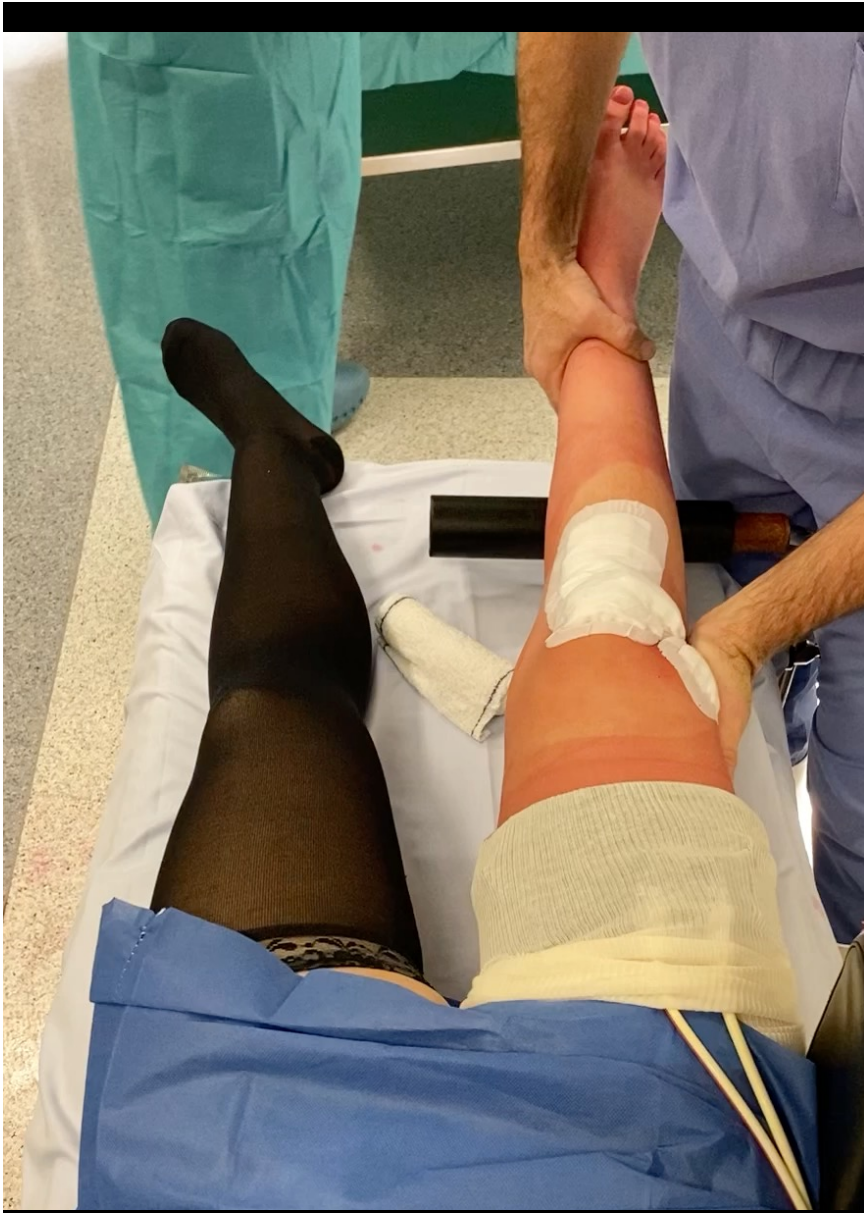Medial approach?

Post-operative care?



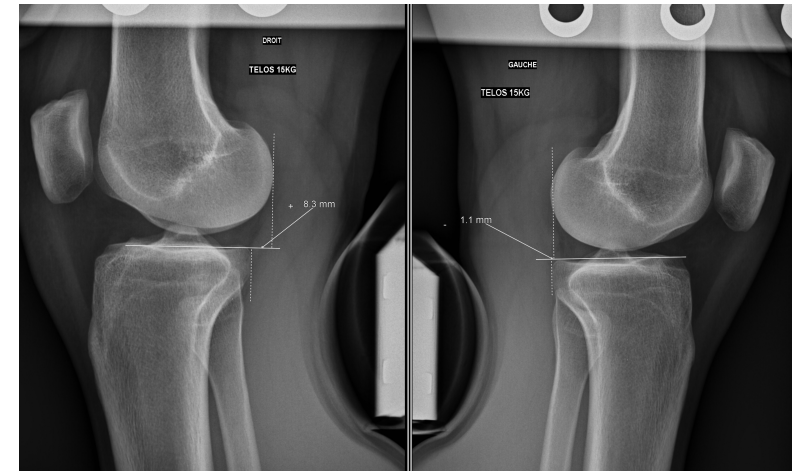






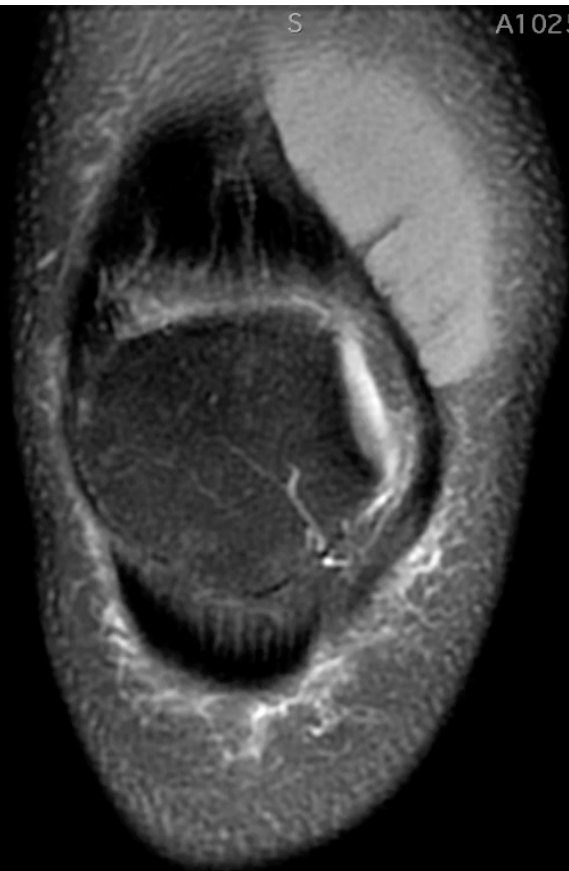
Another example addressed in November 2020

- 19 years old Female Student playing Rugby
- ROM 0/0/140
- Lachman soft end point
- Clunk Pivot Shift
- KT1000 9/4 - STS laxity with telos 9 mm
- Medial laxity in flexion, but not in extension



=> ISOLATED BTB

e size: 512 x 512
size: 1356 x 1356



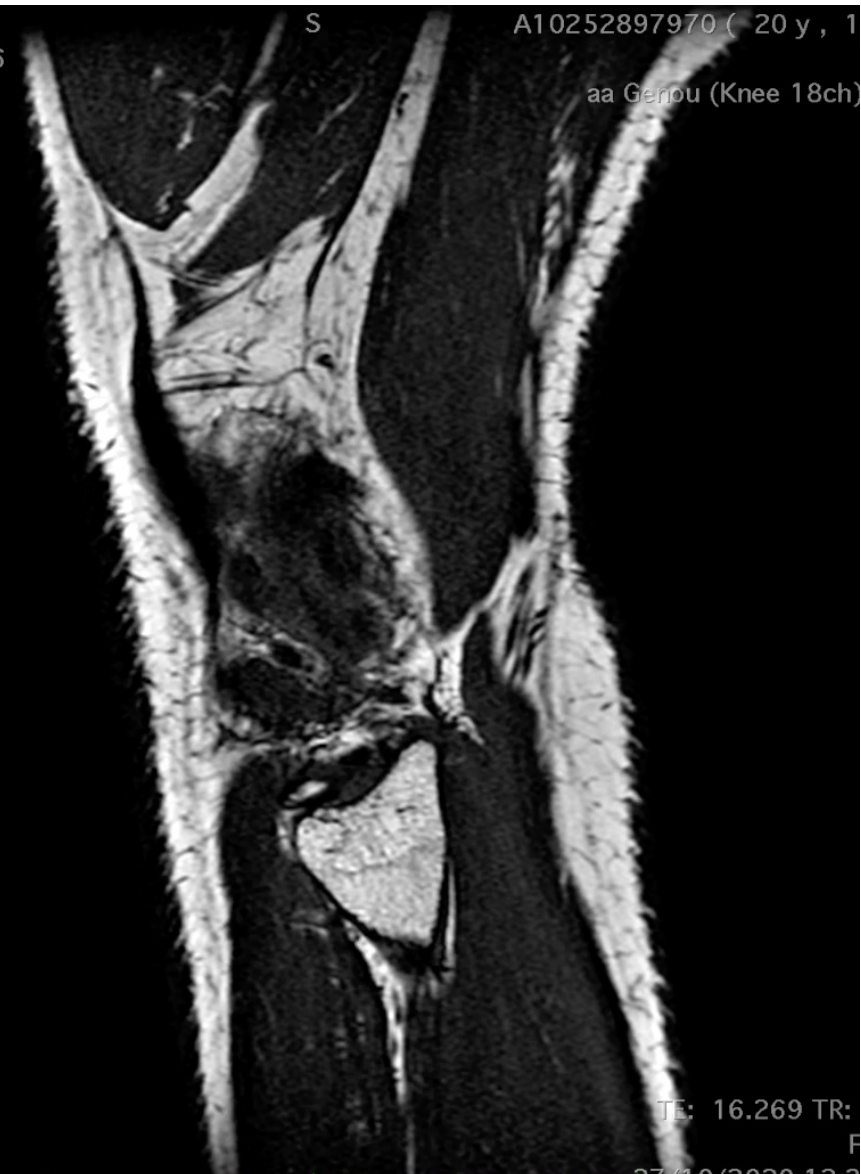S

A10252897970 (20 y , 1
size: 512 x 512
size: 1356 x 1356
aa Genou (Knee 18ch)

TE: 46.116 TR: 3
F

27/10/2020 12:2

e size: 512 x 512
size: 1356 x 1356

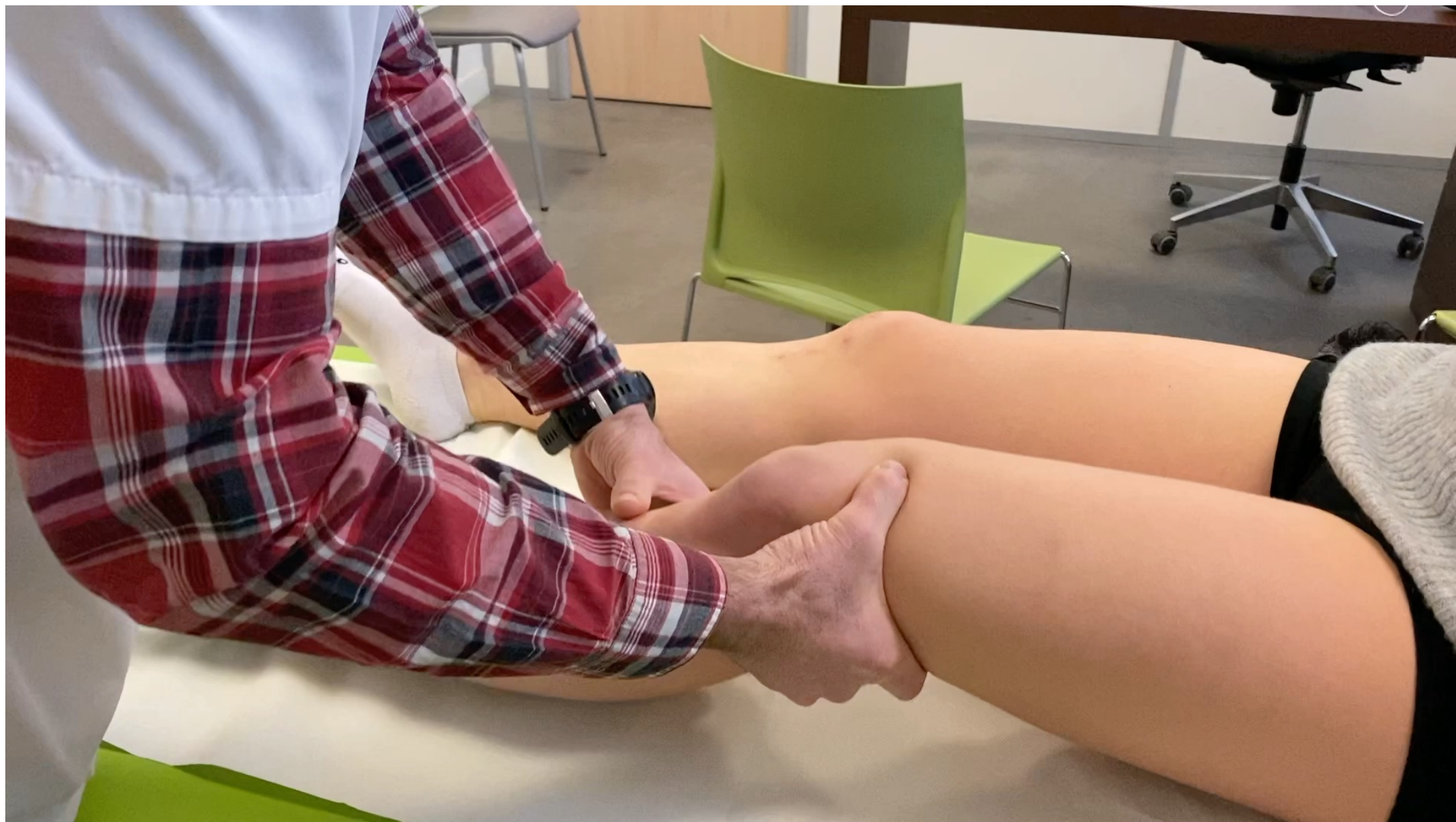

S

A10252897970 (20 y , 1
size: 512 x 512
size: 1356 x 1356
aa Genou (Knee 18ch)

TE: 16.269 TR: 3
F

27/10/2020 12:2



Any comment?

2nd Case: 18 y.o. Male Rugby Player

October 2010

- Professional player
- During a training, support and dislocation of **right** knee
 - ROM 0/0/125
 - Lachman soft end point
 - Clunk Pivot Shift test
 - KT1000 11/4 side to side diff lax: 7 mm
 - Medial joint line pain
- MRI
 - Isolated lesion of ACL

Right Knee

- BTB graft
- MM: partial tear left in place
- LM: Posterior horn flap + middle segment radial crack: debridement
- Cartilage: No lesion

June 2012 (20 y.o.)

New injury: change of direction

- H +
- Instability ++
- Painful point at lateral meniscus (LM)
- Lachman hard delayed end point
- Clunk Pivot Shift
- KT1000 9/5/4
- MRI:
 - Re-rupture ACL

Right Knee

**Revision
QT + LET Deep Lemaire**

How would you explain this failure ?

Any comment on revision ?

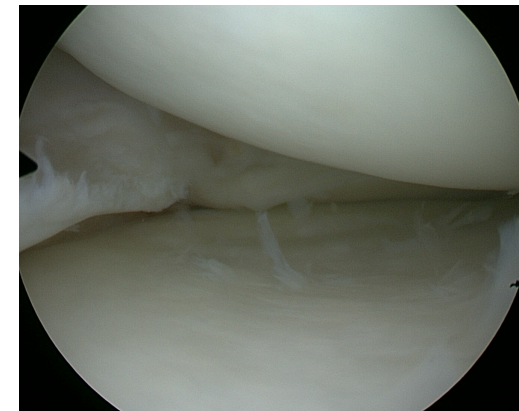
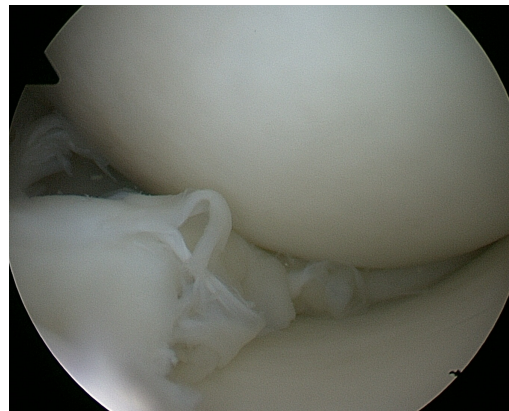
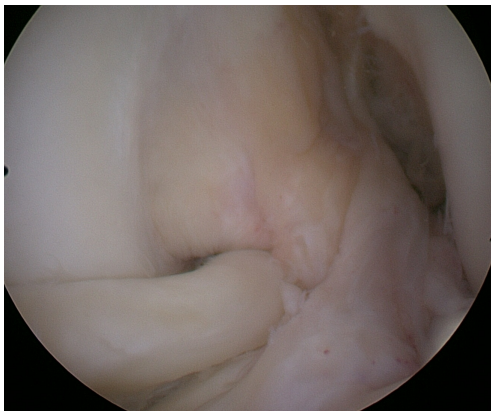
Any advice to prevent new injury ?

February 2014 (22 y.o.)

- 0/5/130
- H + I+ B+(Locked knee)
- Lachman soft end point
- Clunk Pivot Shift
- KT1000 12/6/6. / Telos 10/1
- MRI Isolated lesion of ACL
- Bucket Handle MM

Left Knee

- BTB graft
- MM: subtotal resection
- Cartilage: grade 2 lesion at medial femoral compartment



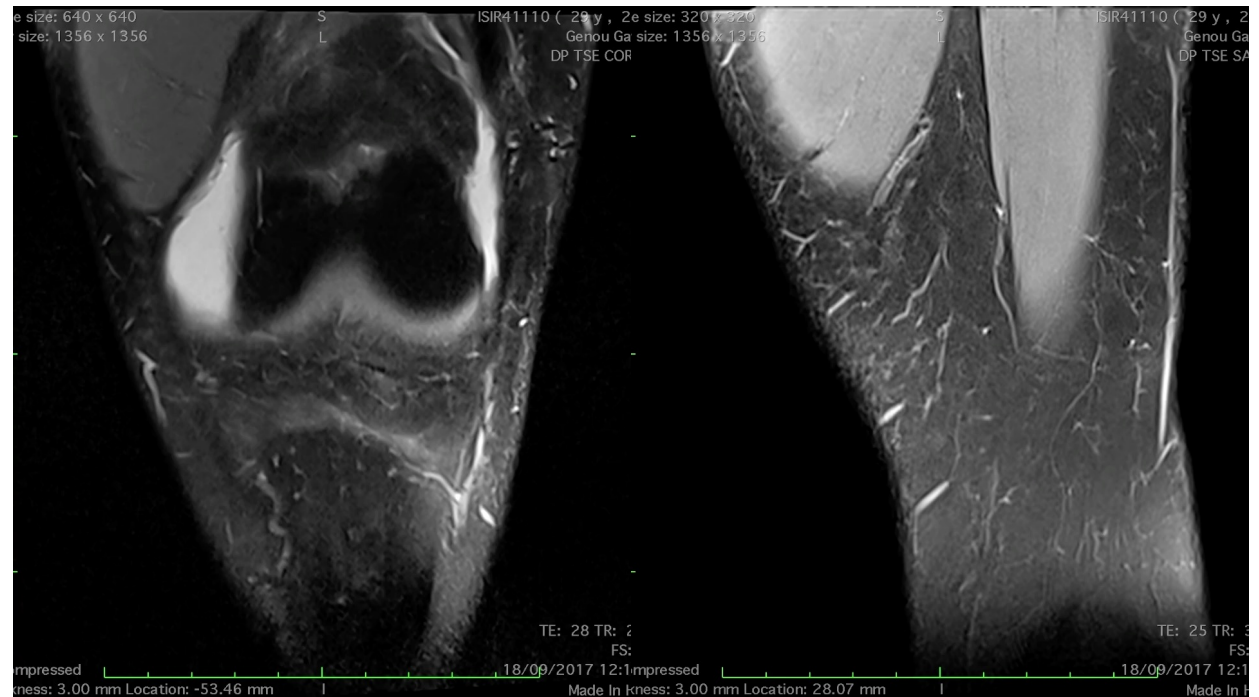
January 2018 (25 y.o.)

New injury fall down on the **left** knee

- ROM 0/0/130
- Lachman soft end point
- Clunk Pivot Shift
- KT1000 10/6
- Telos 15/3

Left Knee

**Revision
QT + LET Deep Lemaire**

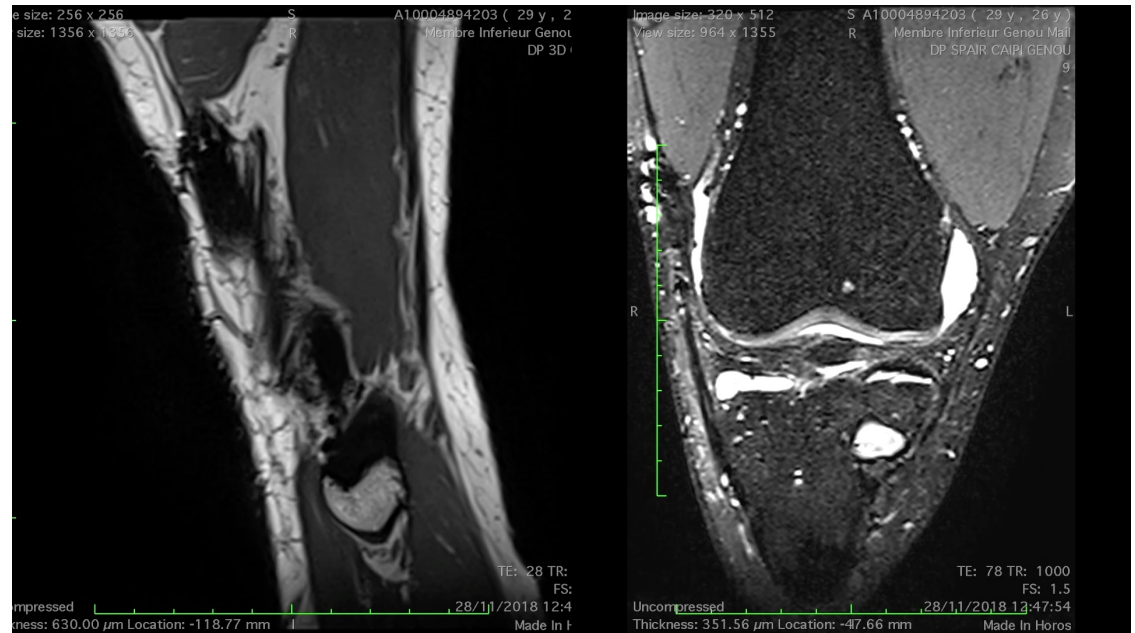


December 2018

back to office with an MRI of both knees and abnormal aspect of the grafts

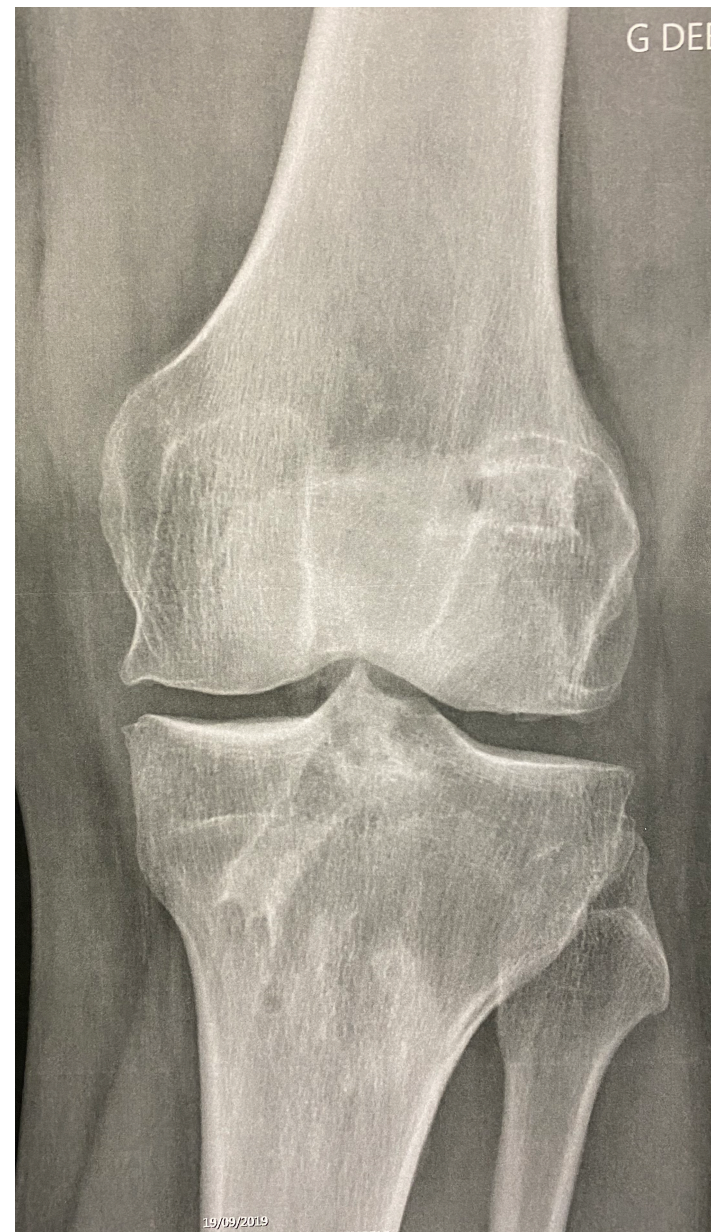
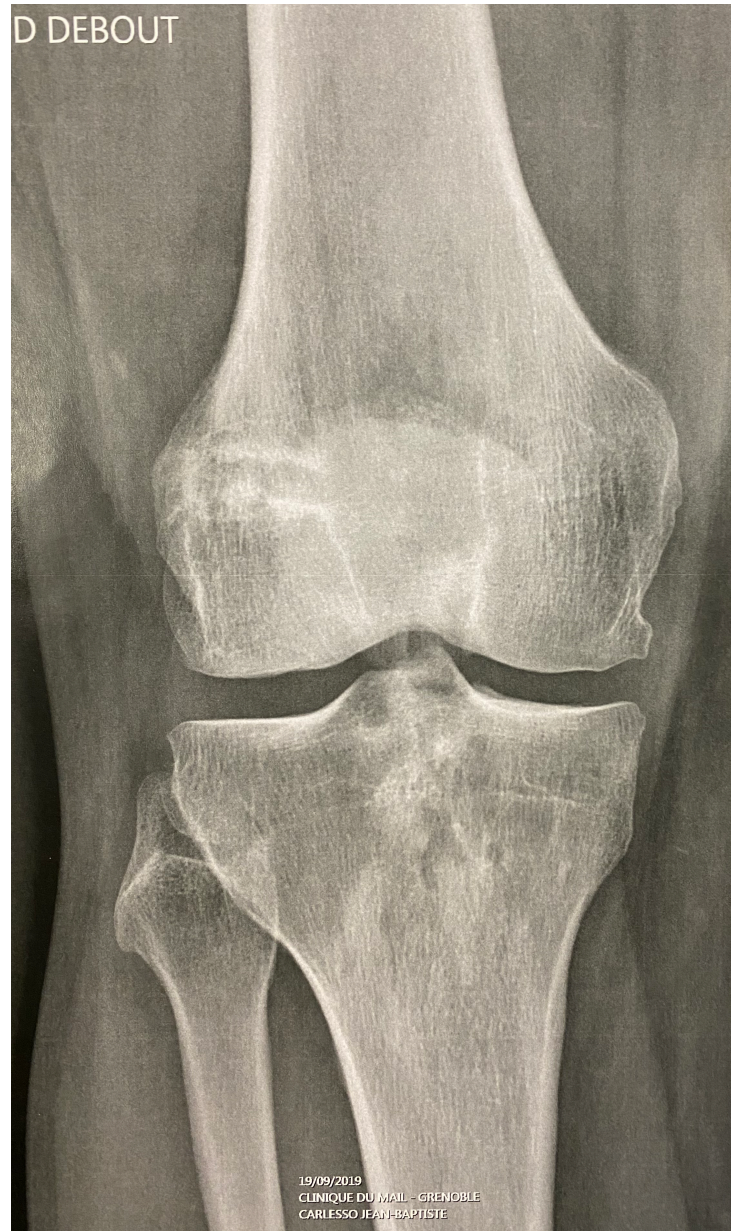- Bilateral delayed hard end point
- Bilateral Equal Pivot Shift Telos 7/6
- Stopped to play (unable)

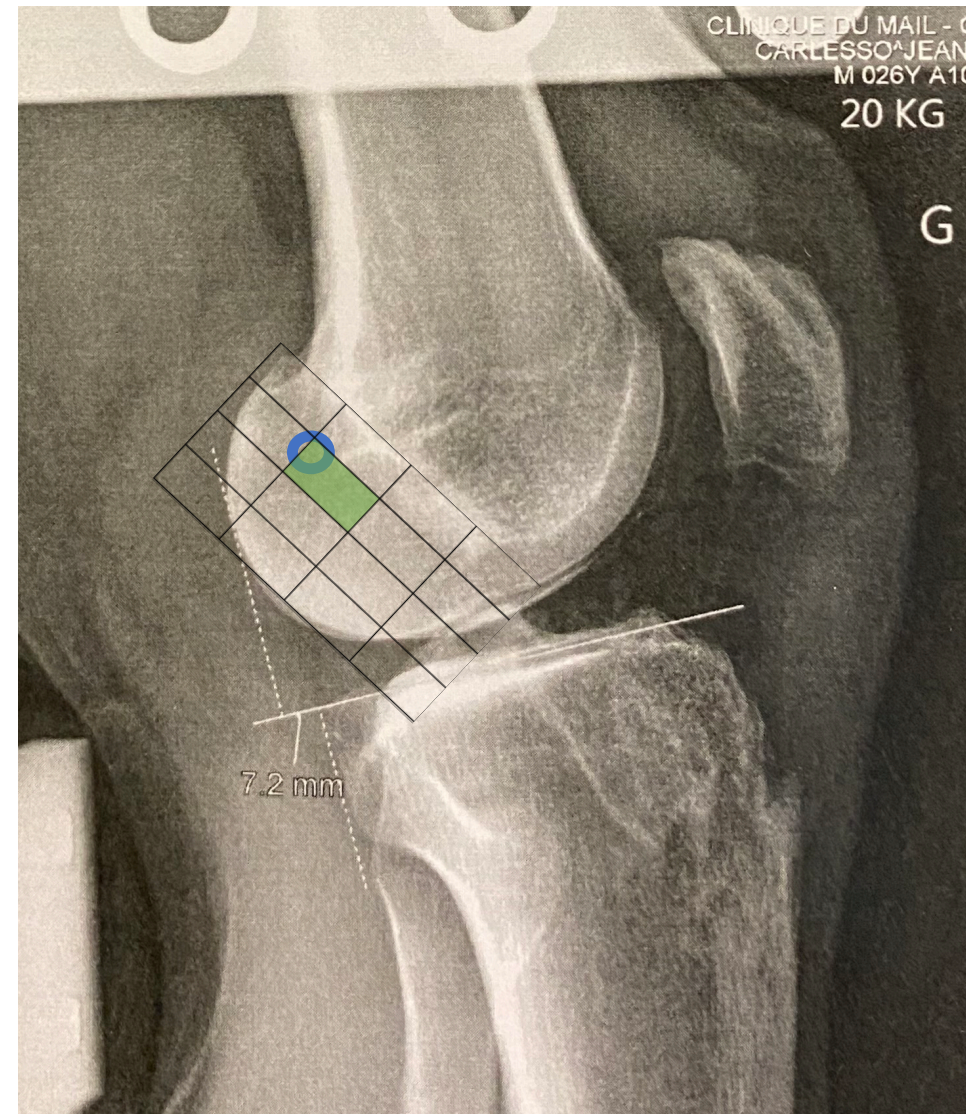
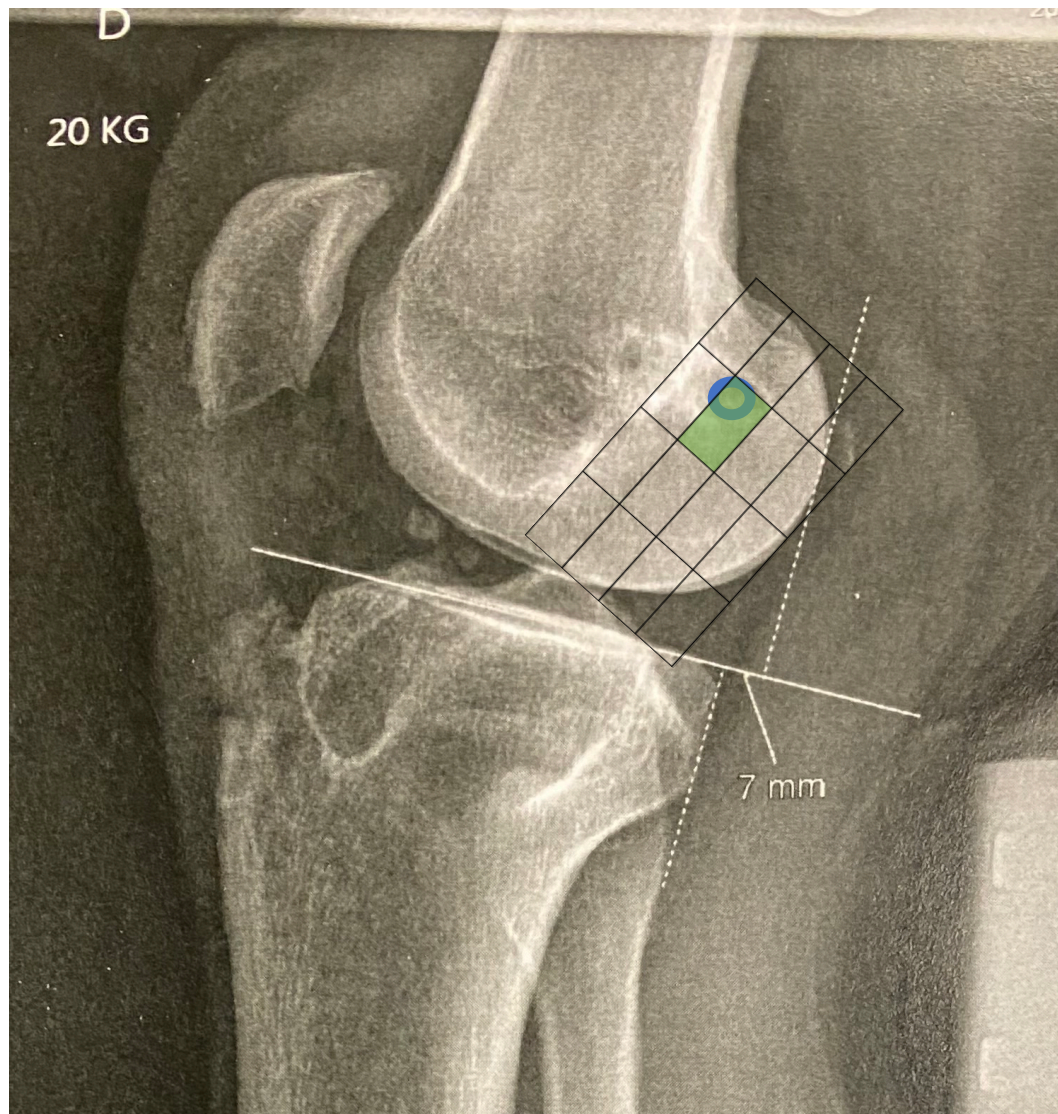
Both Knees



**How do you explain the resorption
of the grafts without injury?**

**Which investigation
do you ask for?**





1. Non-anatomic tunnel position increase the risk of revision ACL reconstruction [K.J. Byrne and J.D. Hughes](#) *Knee Surg Sport Traum Arthroscopy*. 2021

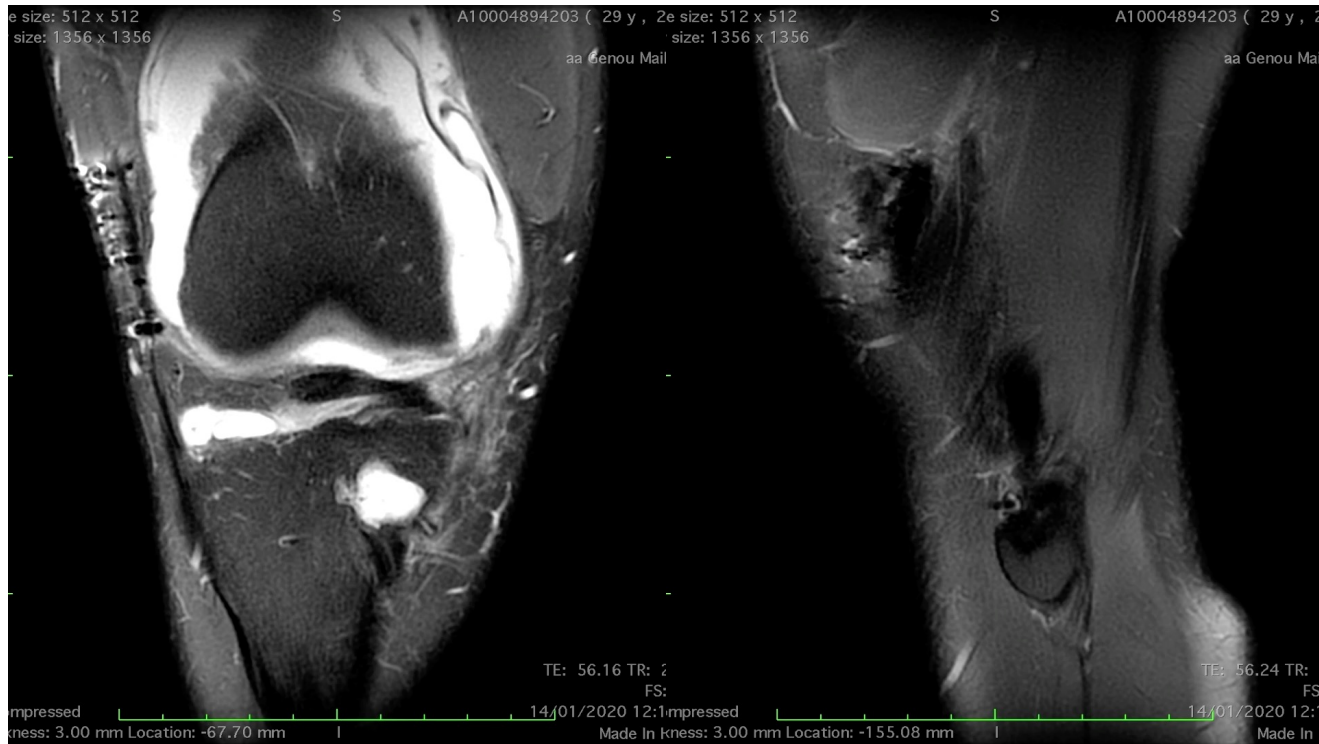
**What is your advise to the patient?
What would you do?**

March 2019

Went back to sport

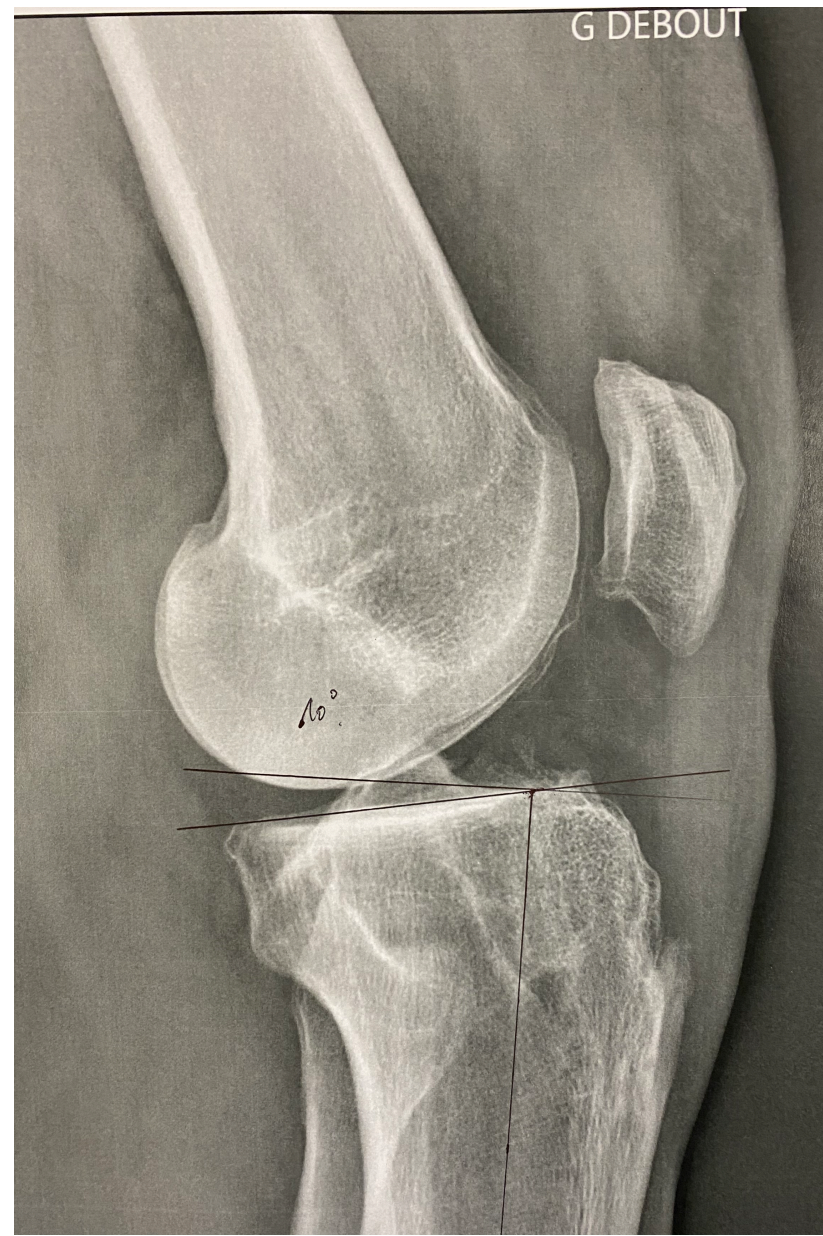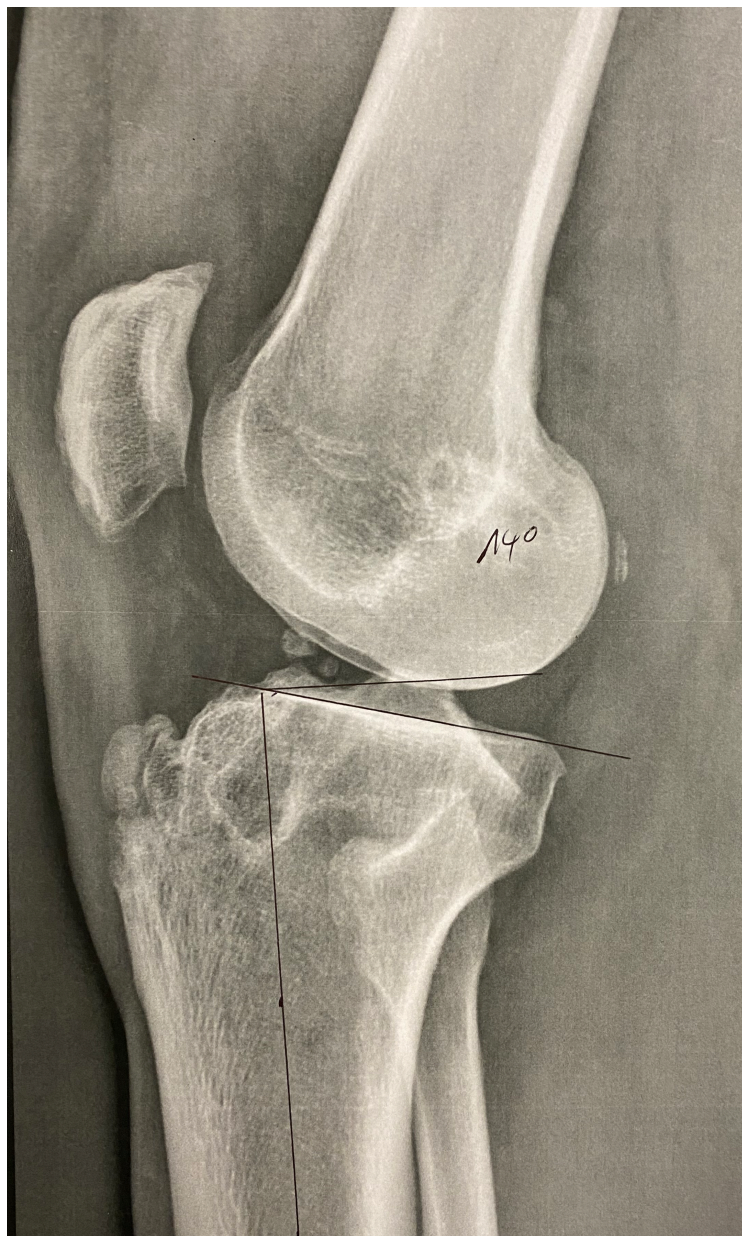Locked knee

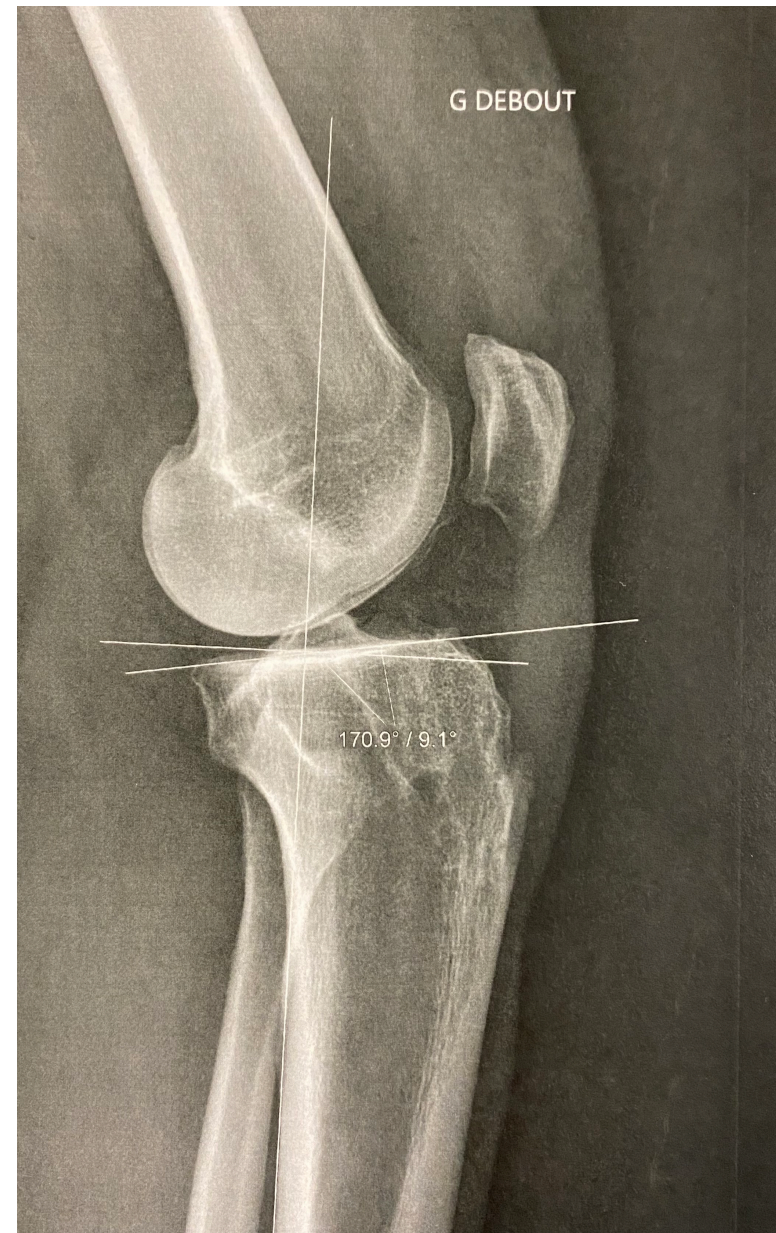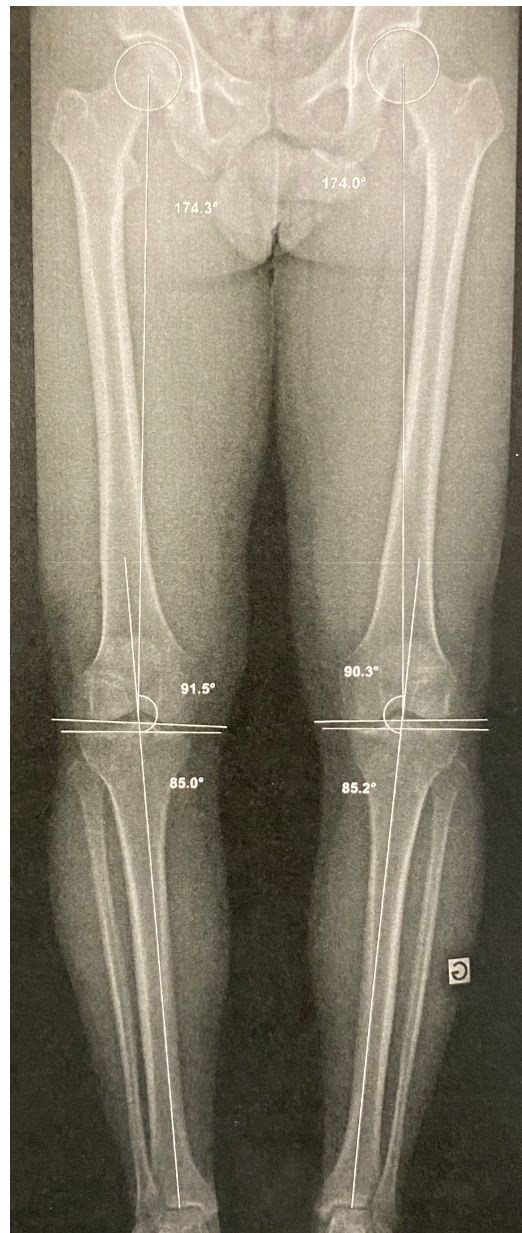
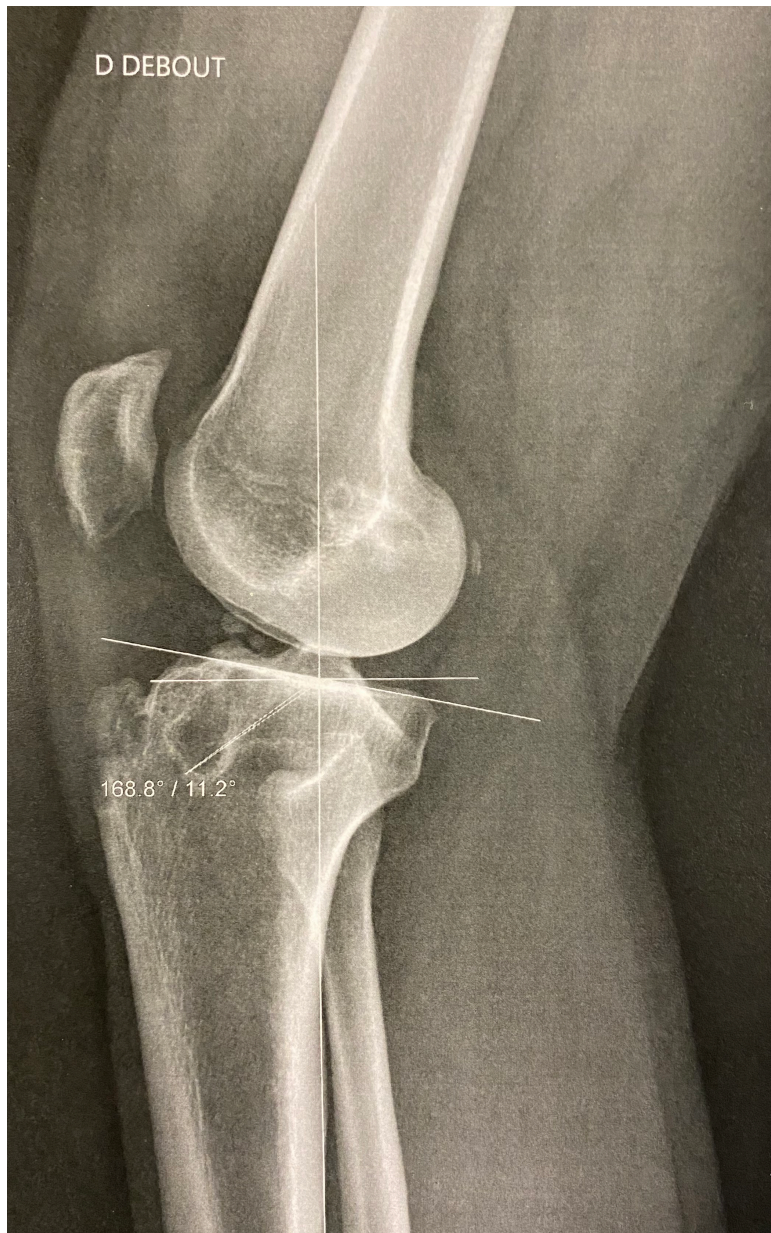
would like to play rugby and to ski...



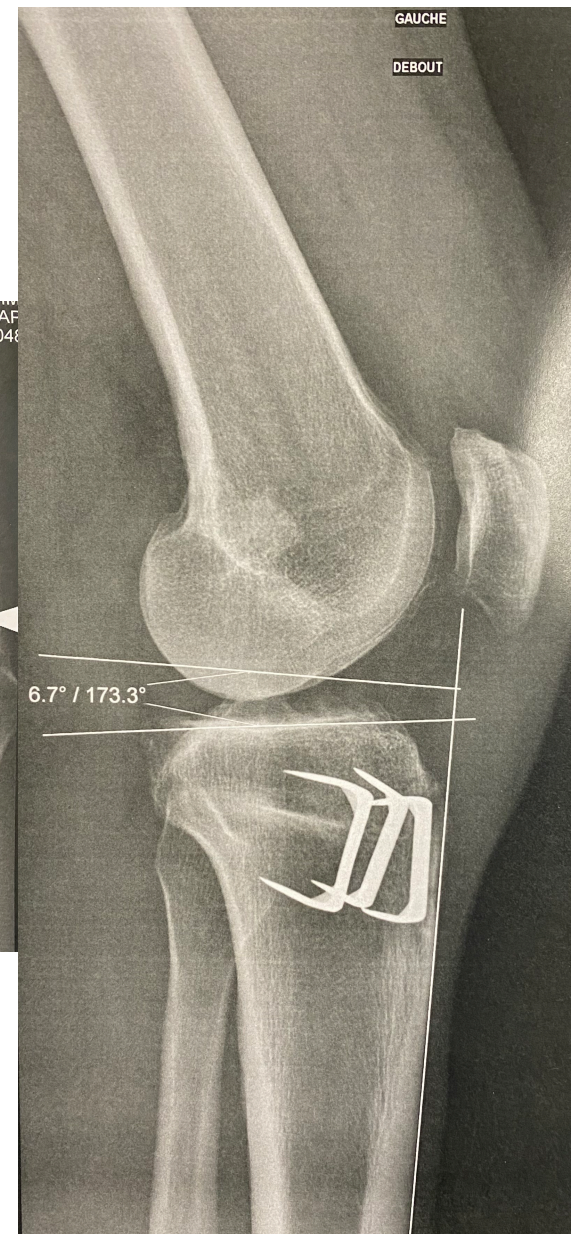
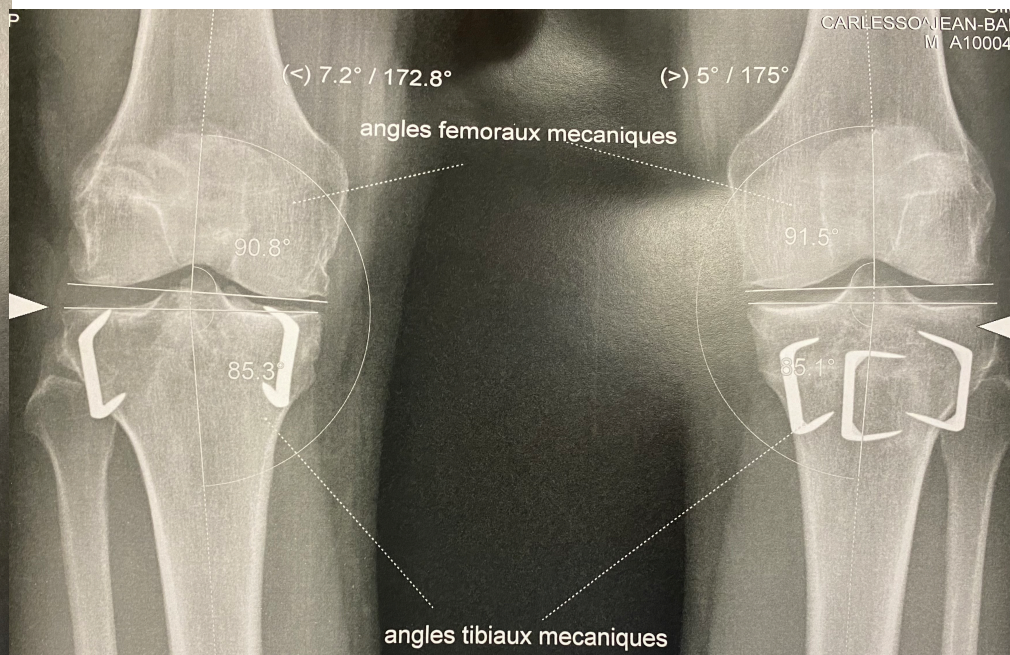
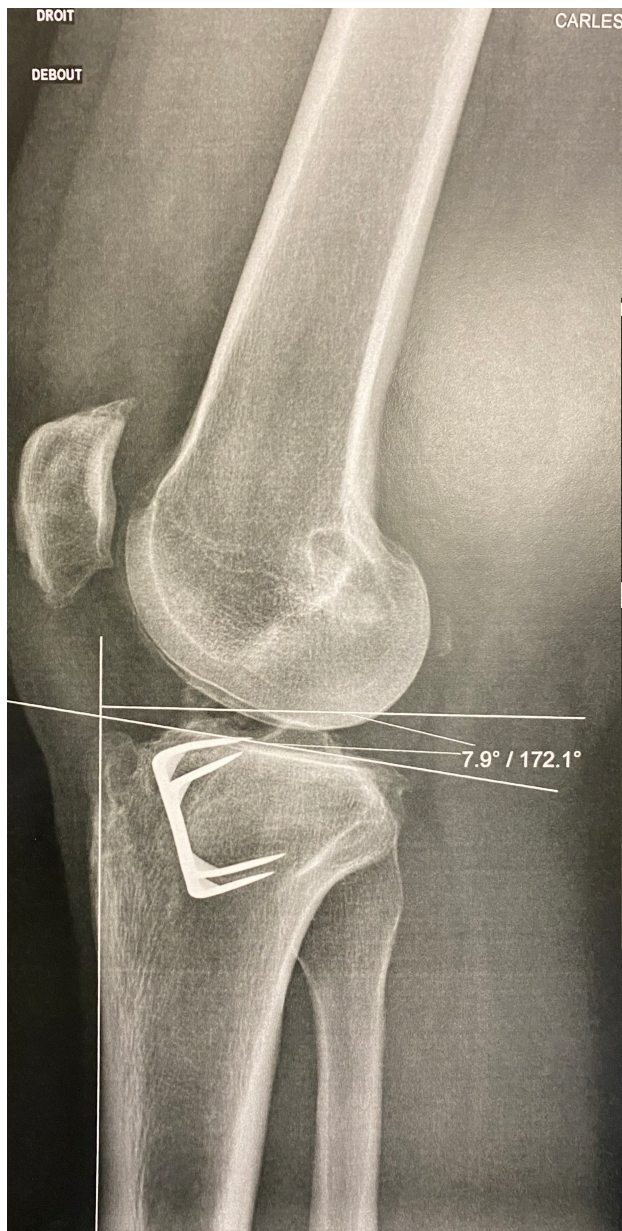
Right Knee

Simple Meniscectomy ?
Suture ?
Revision ACL surgery ?

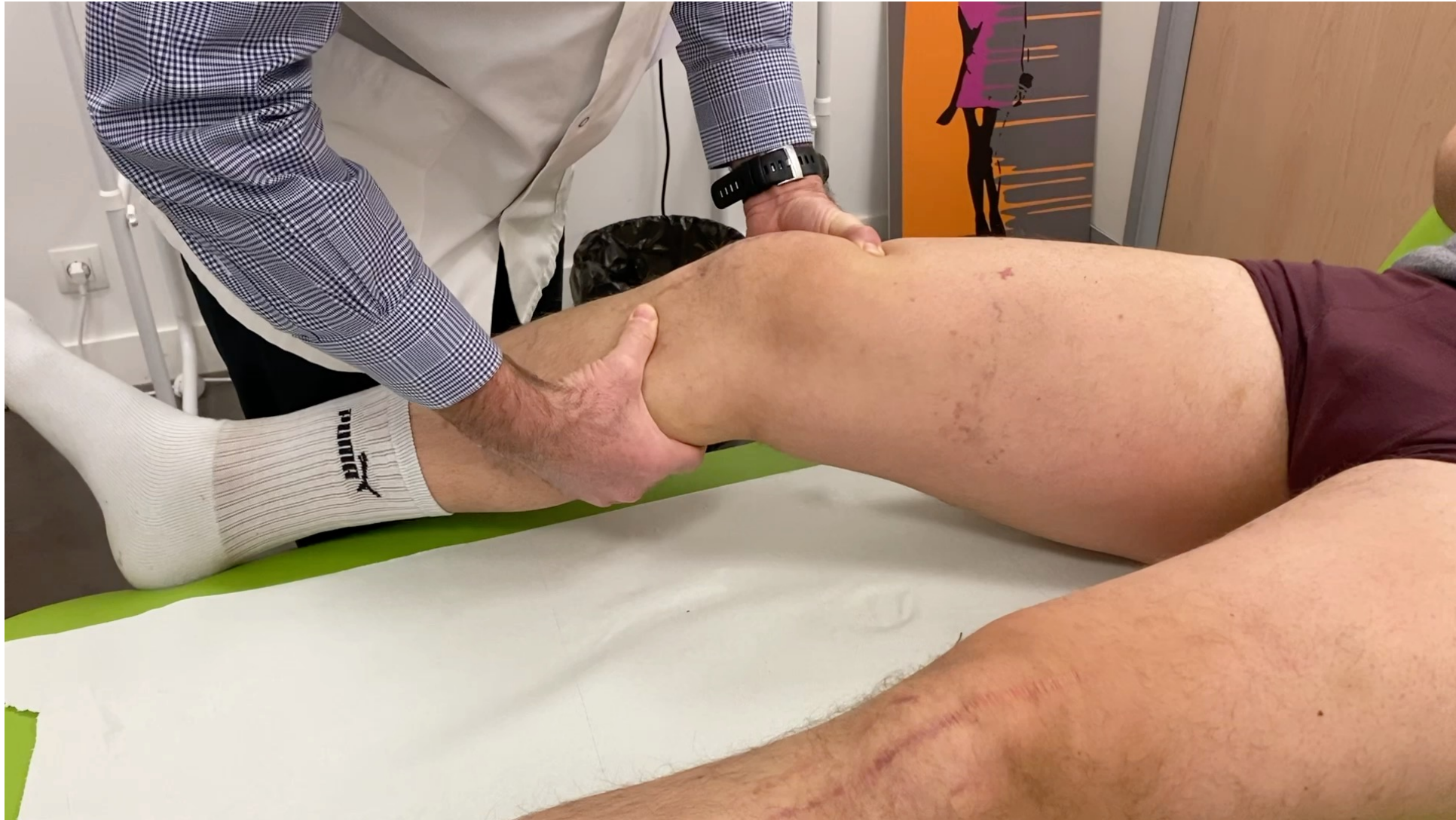



How do you manage?
Any surgery?

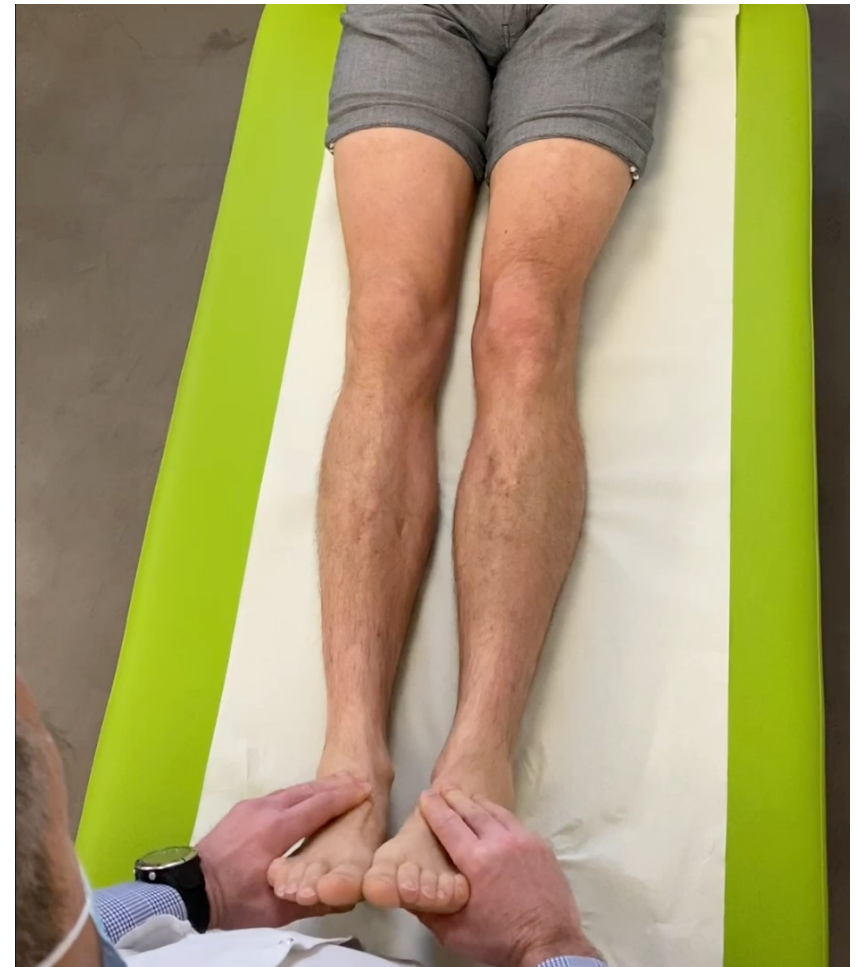

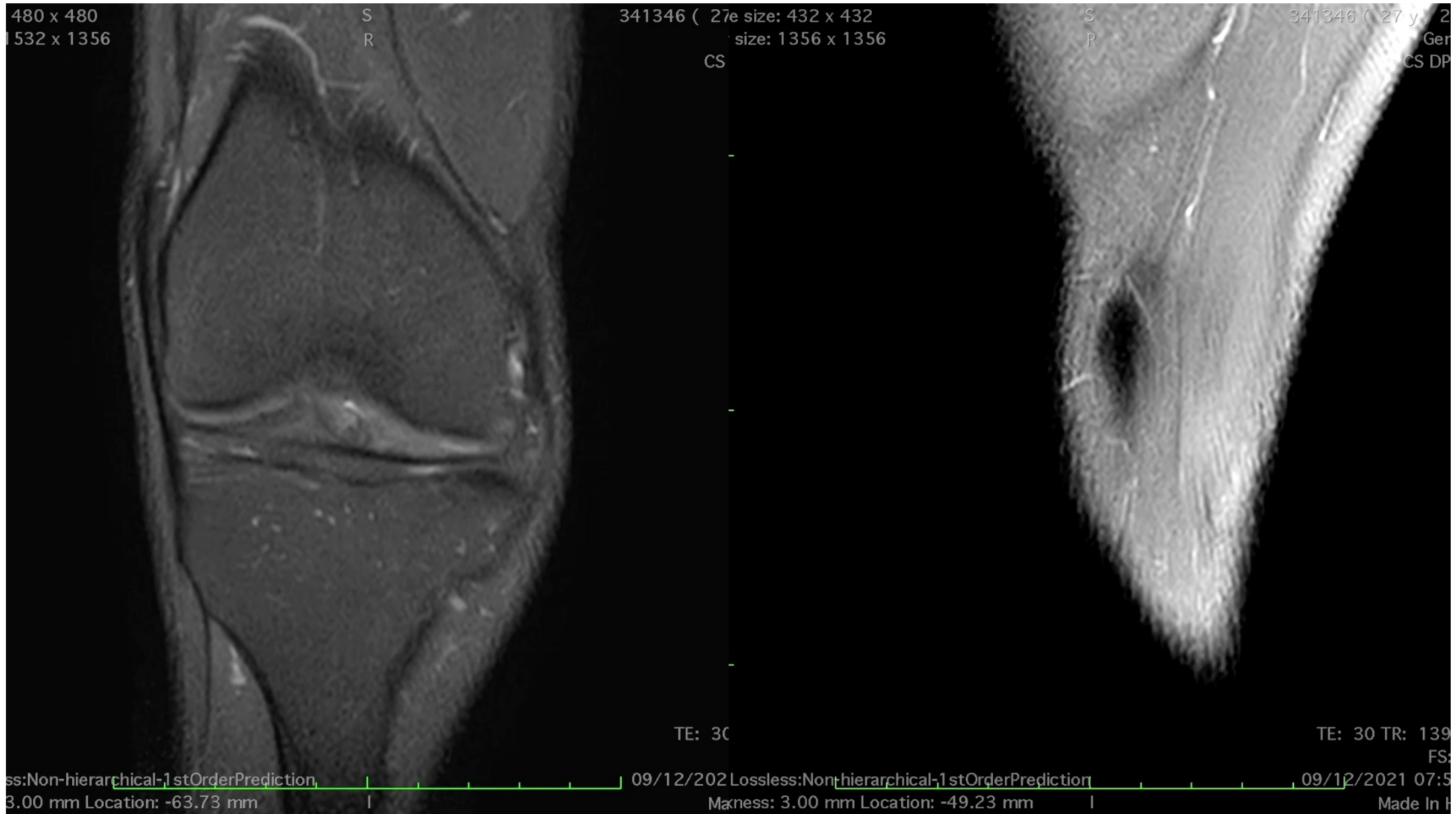
January 2022



3rd Case: 27 y.o. Male physiotherapist high level motorcycle trial

- At 8 years old rupture of ACL (fracture tibial spine) + suture Lateral Meniscus
- At 12 years old, failure of the suture of LM: Meniscectomy
- Complain: anterior knee Pain





480 x 480
1532 x 1356

S
R

341346 (27e size: 432 x 432
size: 1356 x 1356
CS

S
R

341346 (27 y, 2
Ger
CS DP

TE: 30

TE: 30 TR: 139

FS:

ss:Non-hierarchical-1stOrderPrediction

09/12/202 Lossless:Non-hierarchical-1stOrderPrediction

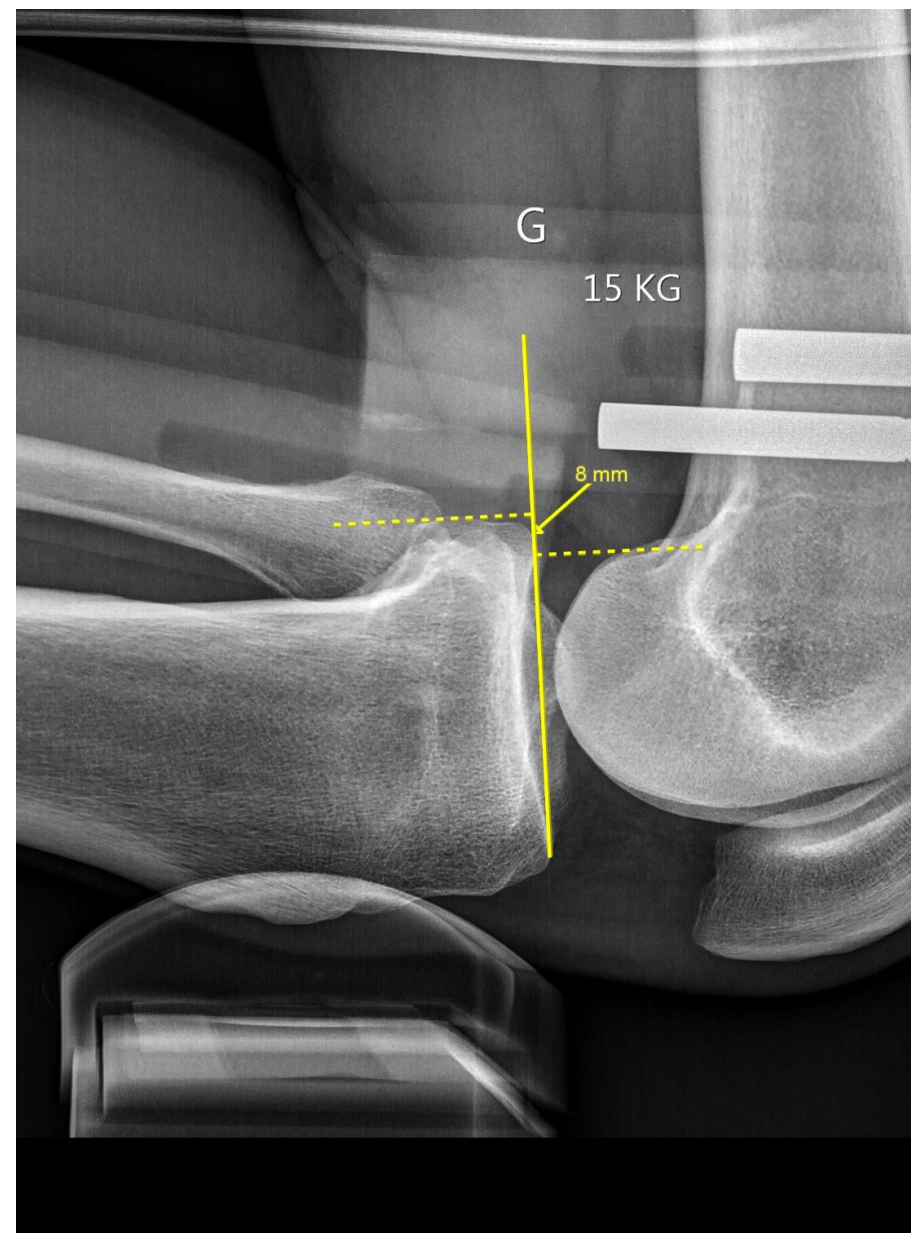
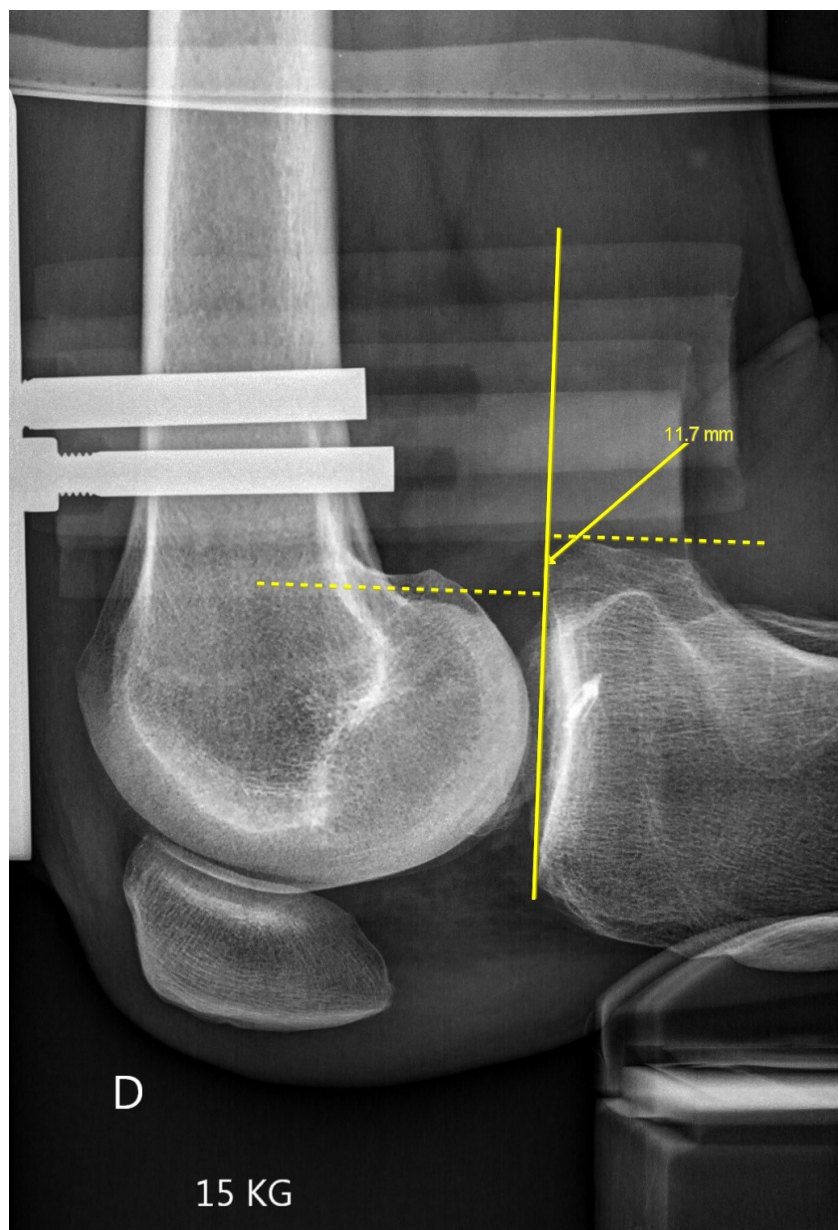
09/12/2021 07:5

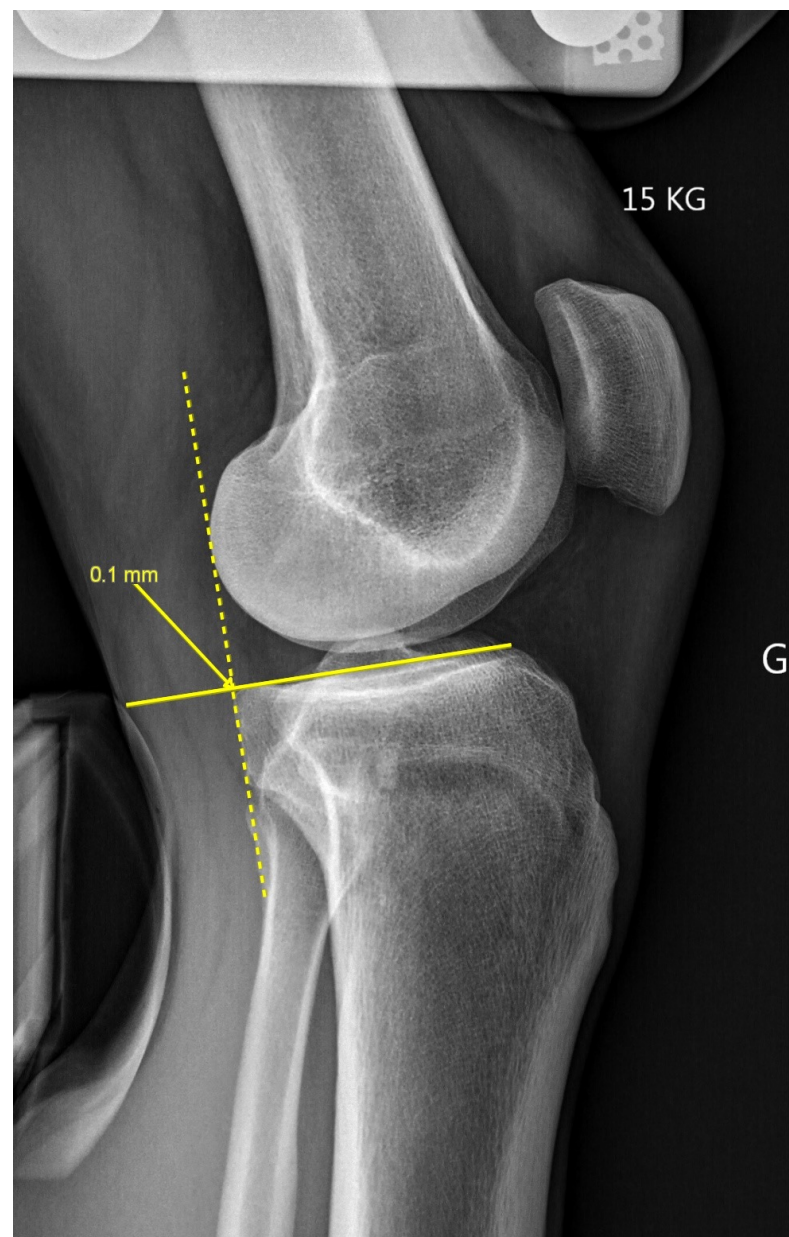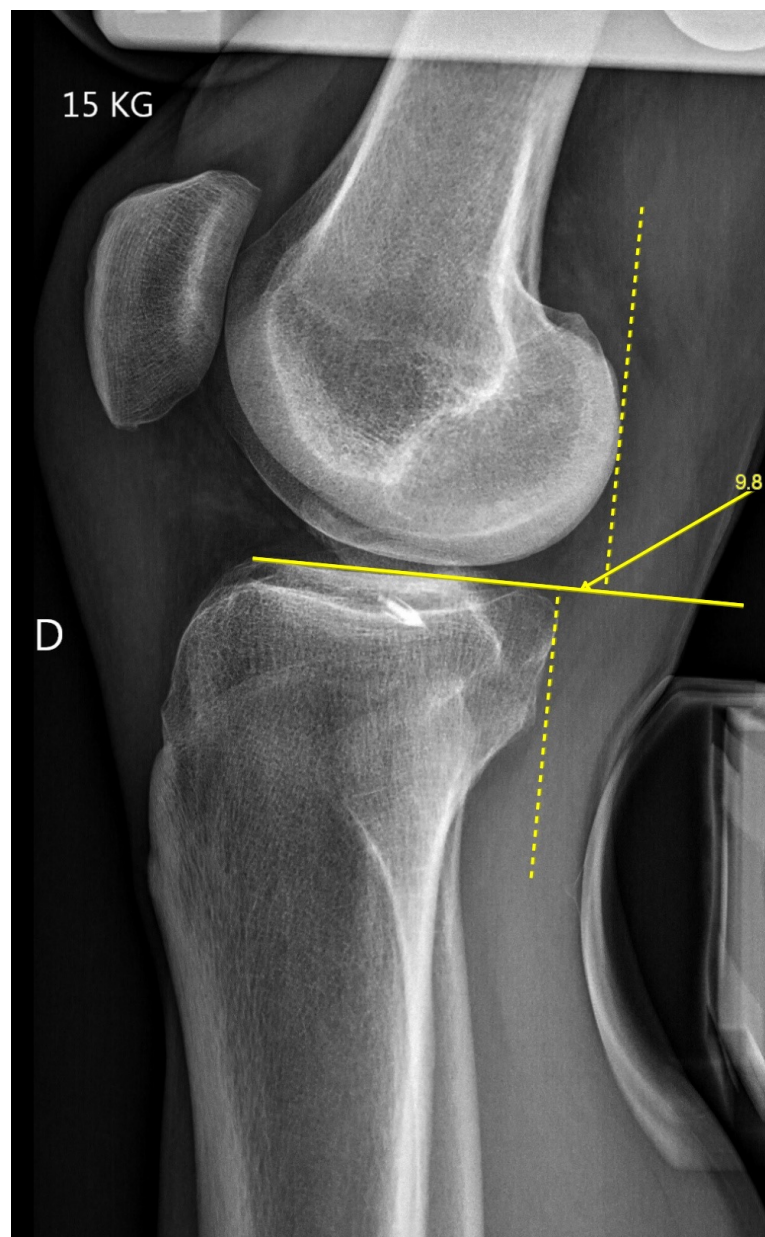
3.00 mm Location: -63.73 mm

Maxness: 3.00 mm Location: -49.23 mm

Made In H

Any other investigation ?
What is your management ?





Any surgery ?
Advice to the patient ?